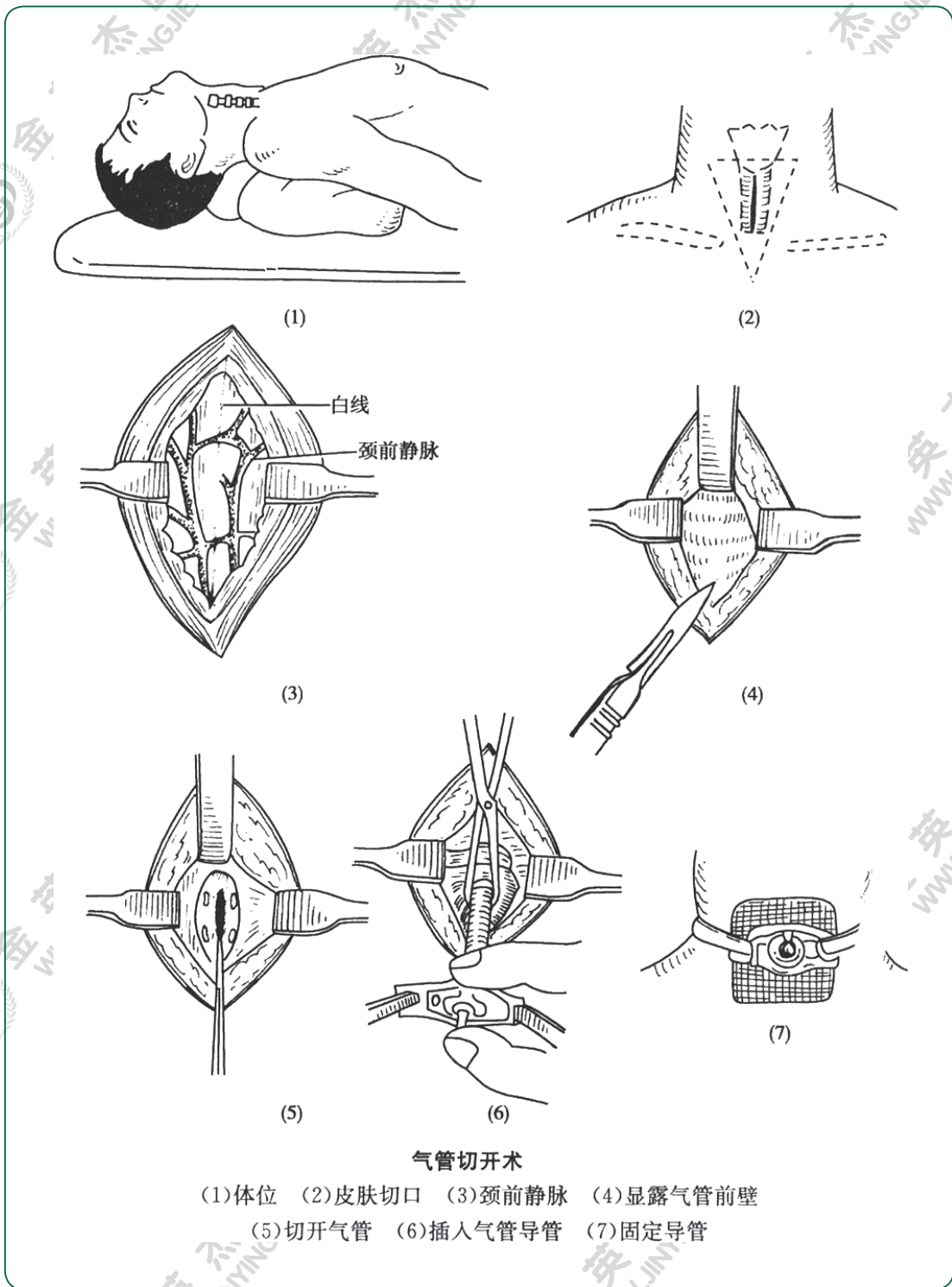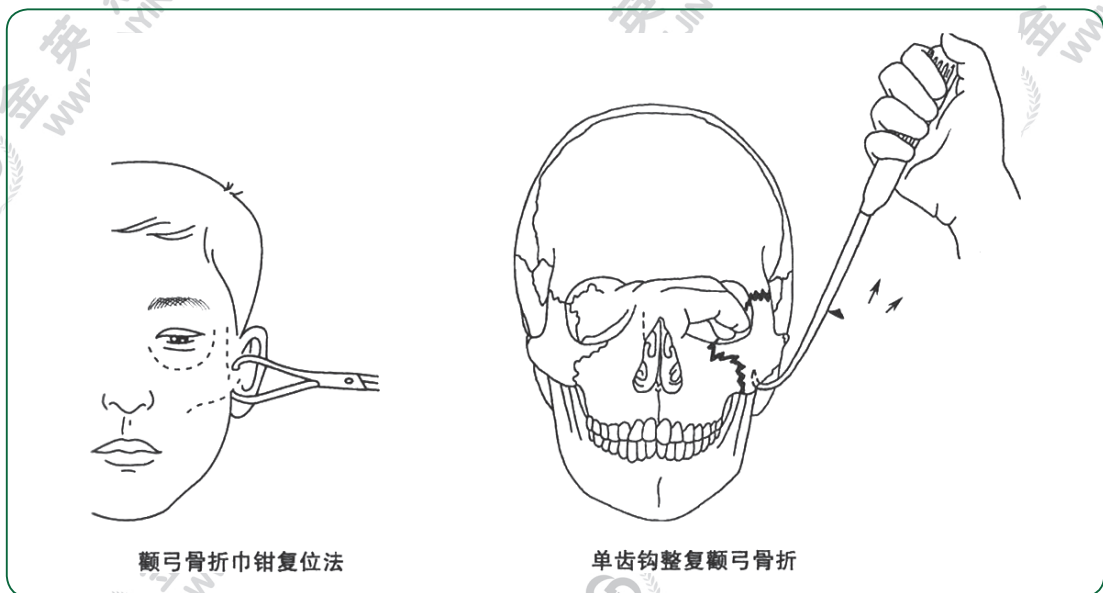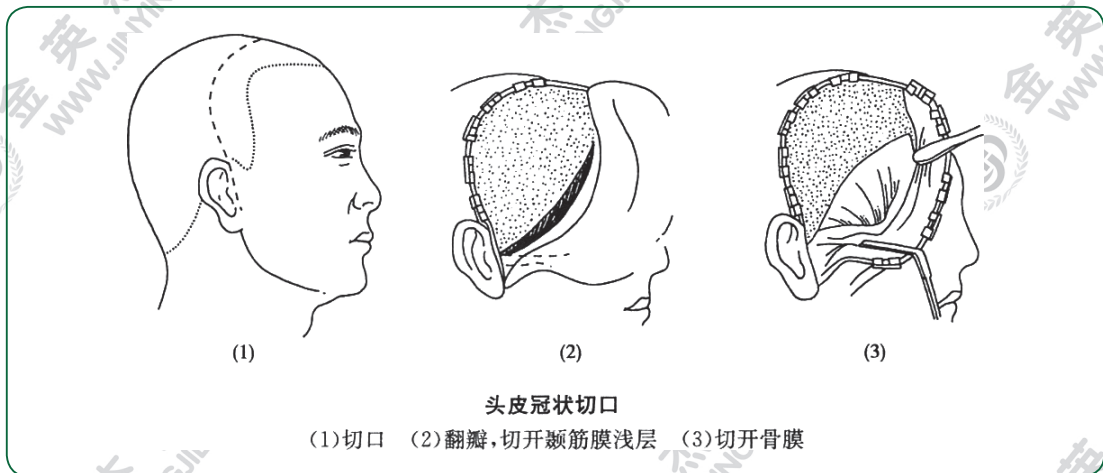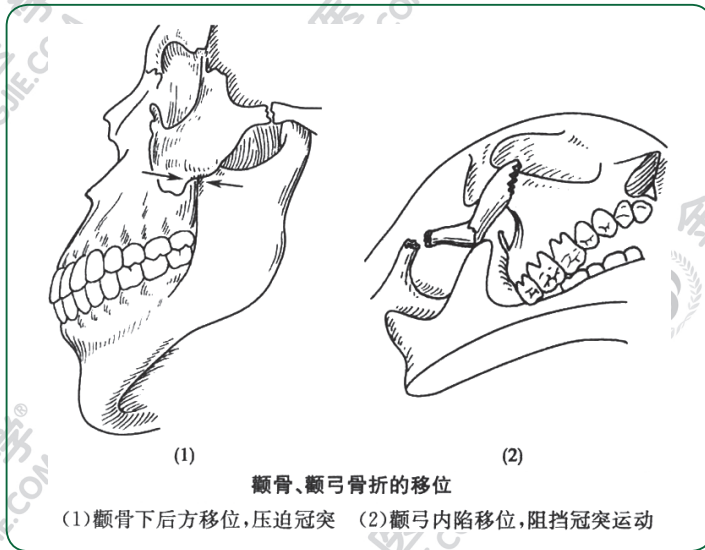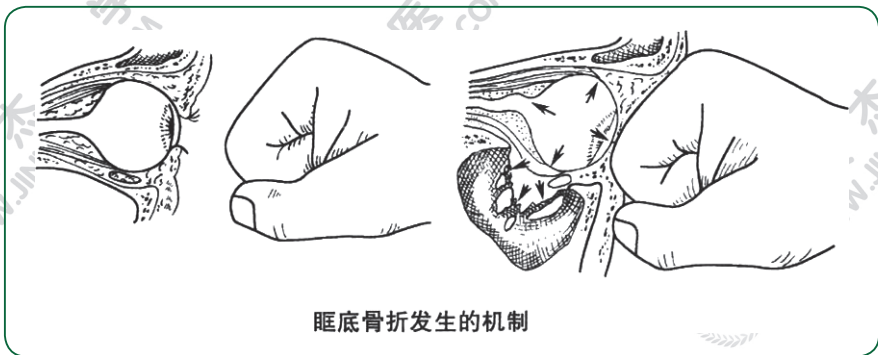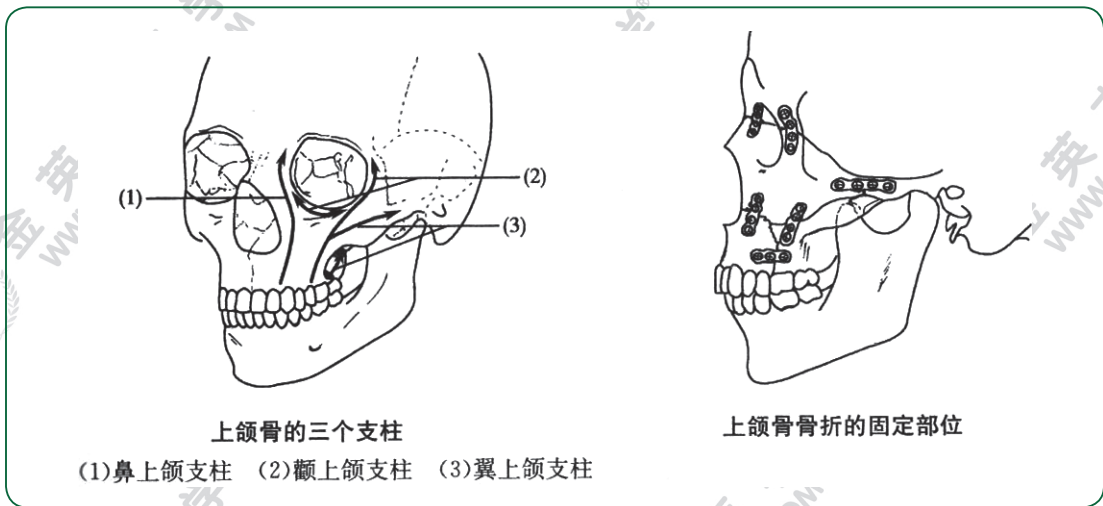


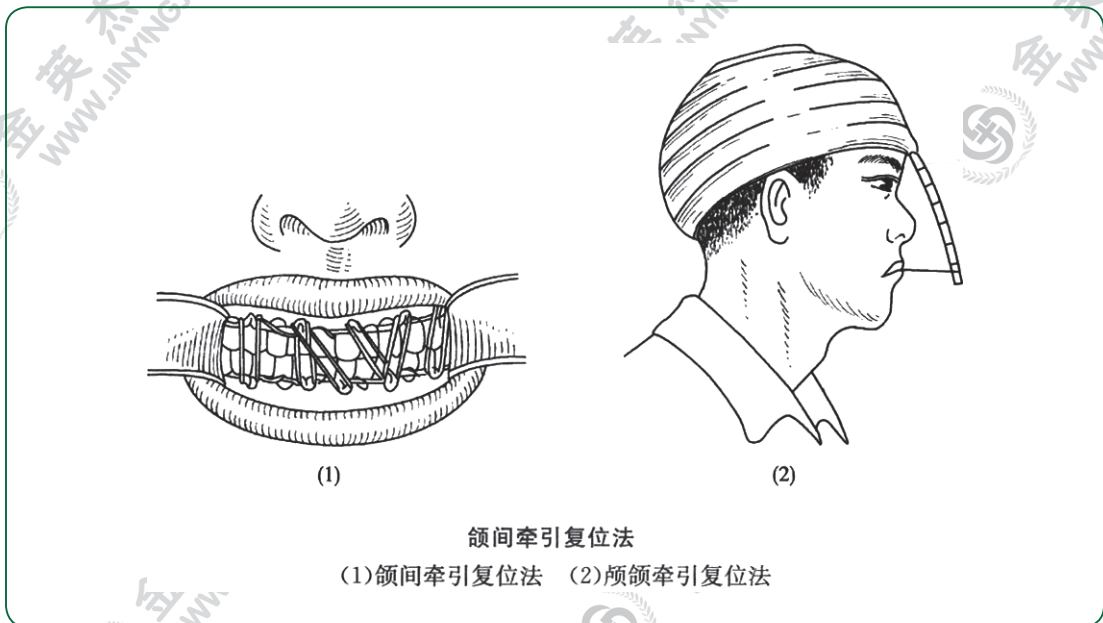
眶底骨折发生的机制



上颌骨三个支柱

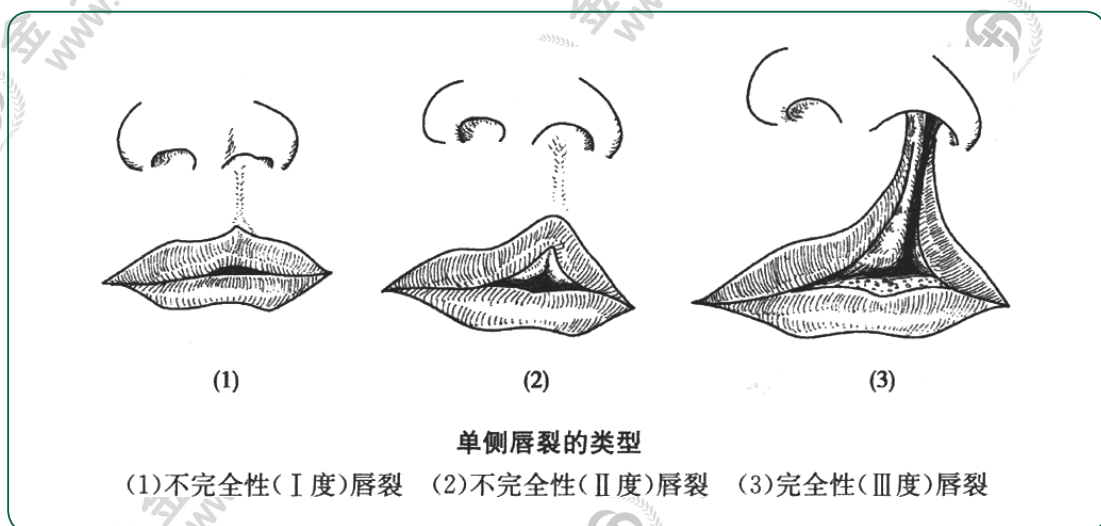
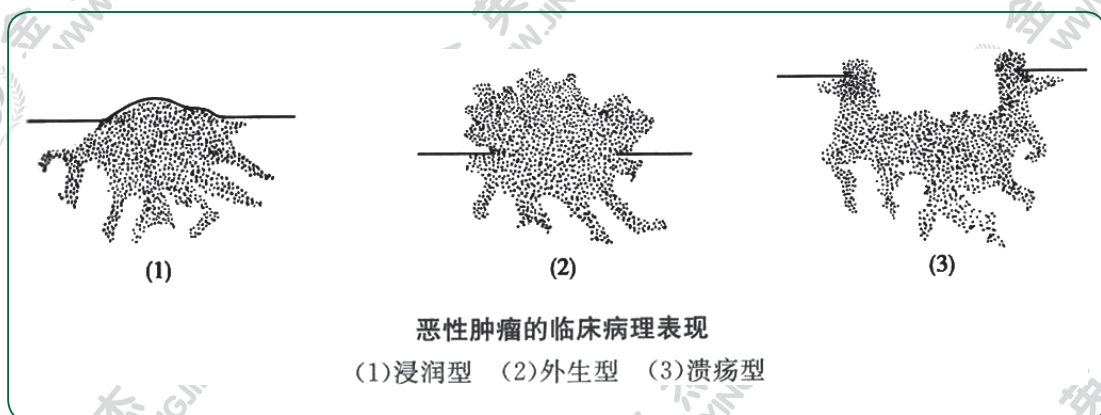
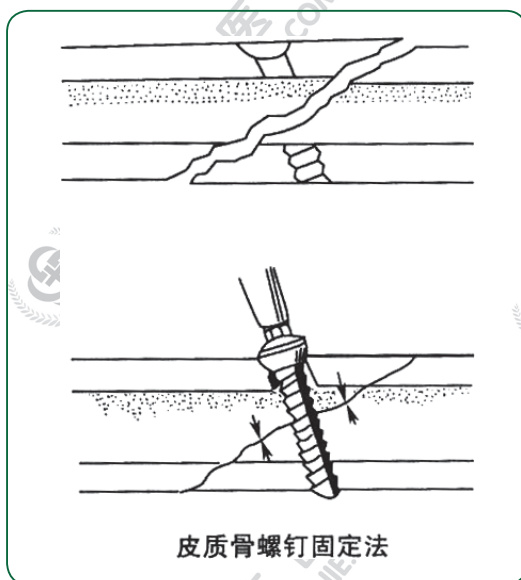
(1)鼻上颌支柱 (2)颧上颌支柱 (3)翼上颌支柱

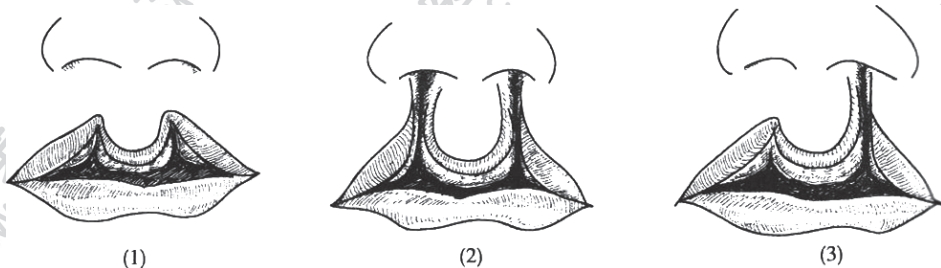
上颌骨骨折的固定部位



颌间牵引复位法

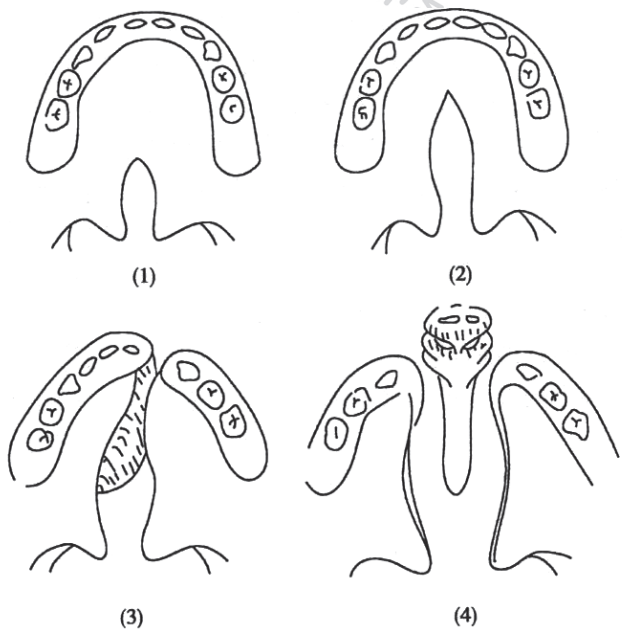
(1)颌间牵引复位法 (2)颅颌牵引复位法





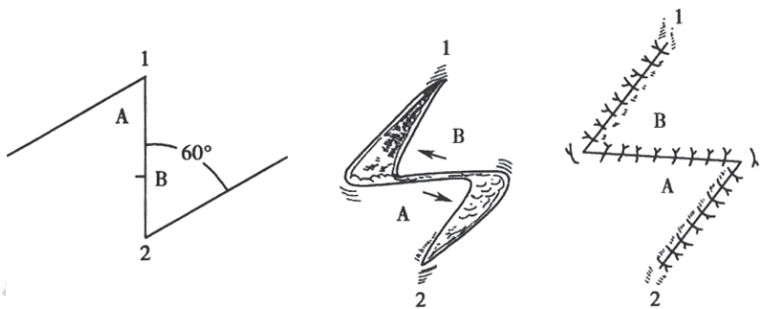
双侧唇裂的类型

- (1) 双侧不完全性(双侧 II 度)唇裂 (2) 双侧完全性(双侧 III 度)唇裂  
 (3) 双侧混合性(左侧 III 度, 右侧 II 度)唇裂

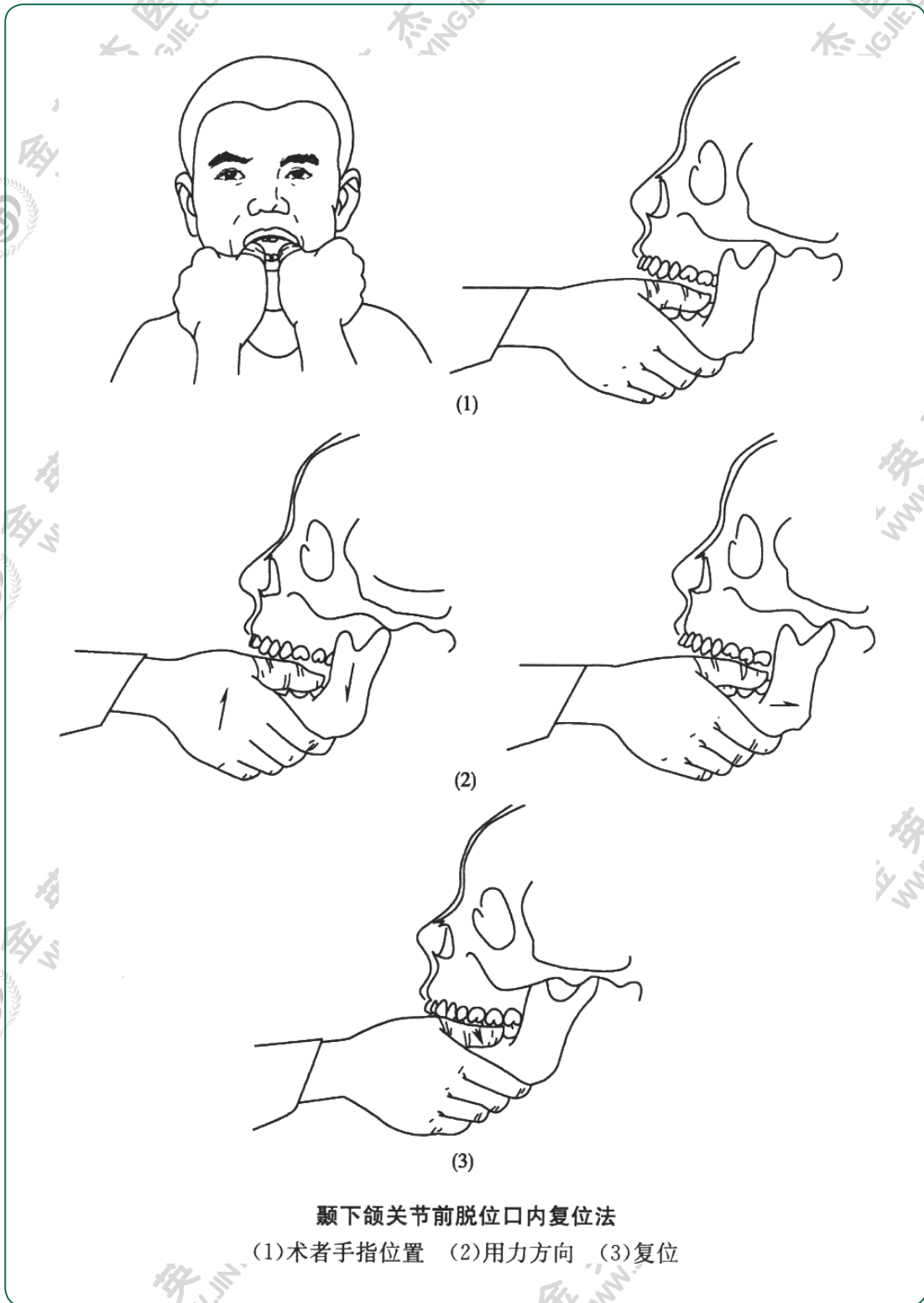


腭裂的临床分类

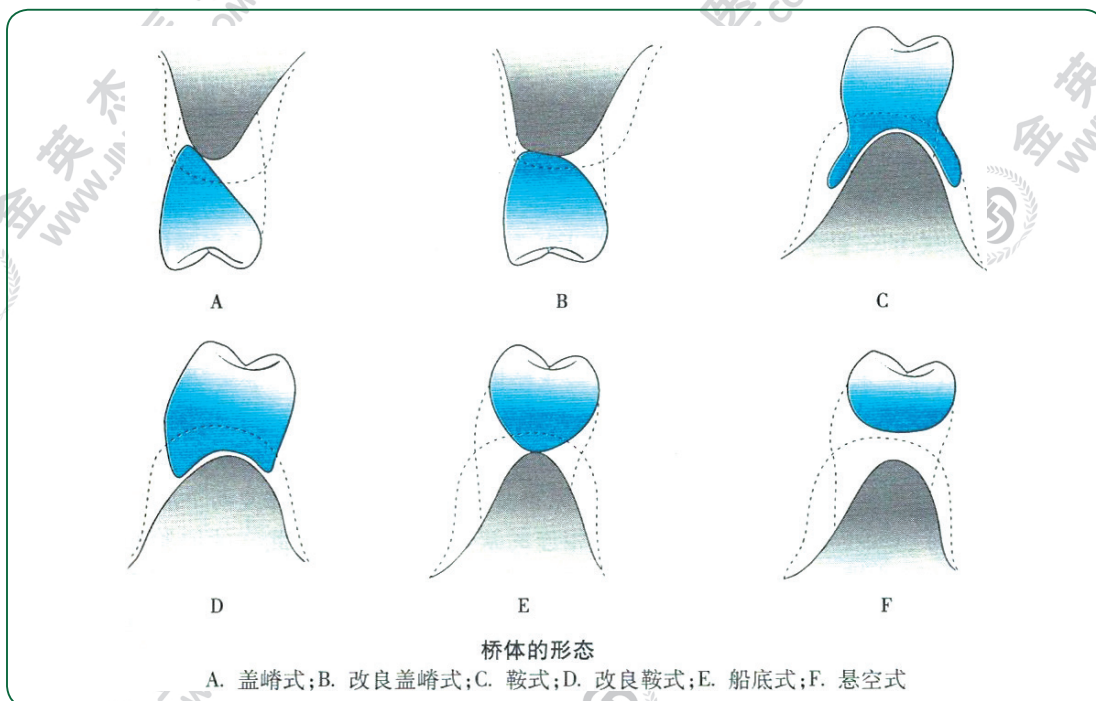
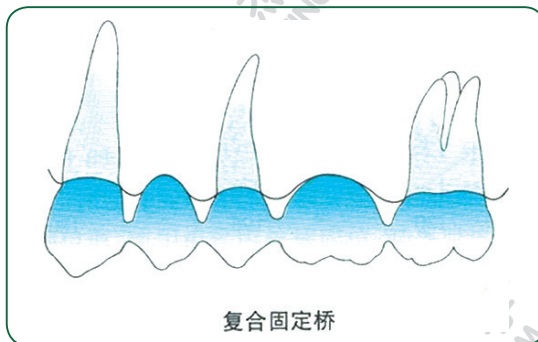
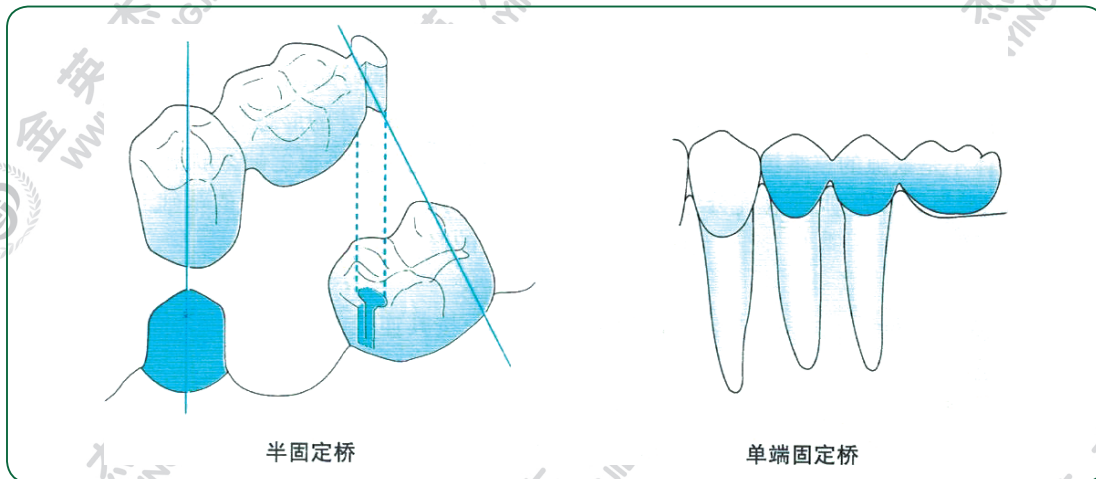
- (1) 软腭裂 (2) 不完全腭裂 (3) 单侧完全性腭裂 (4) 双侧完全性腭裂

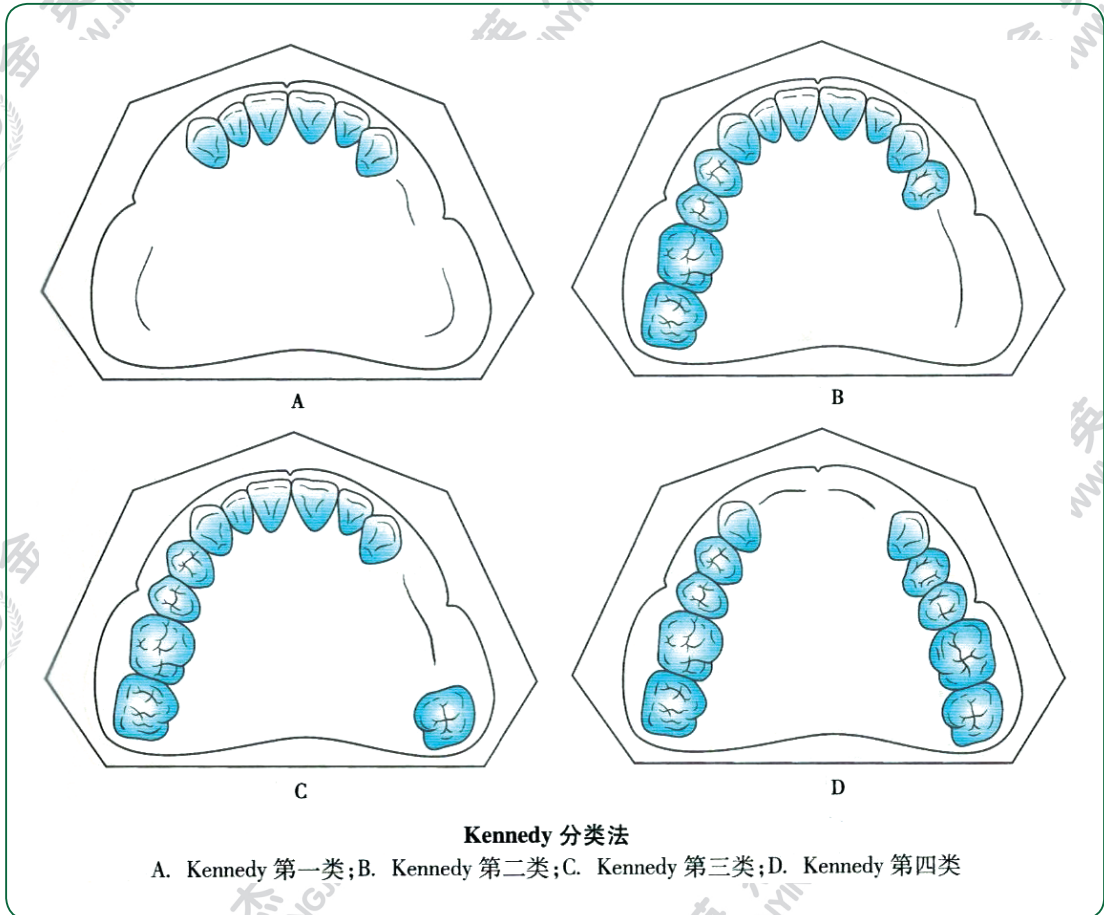
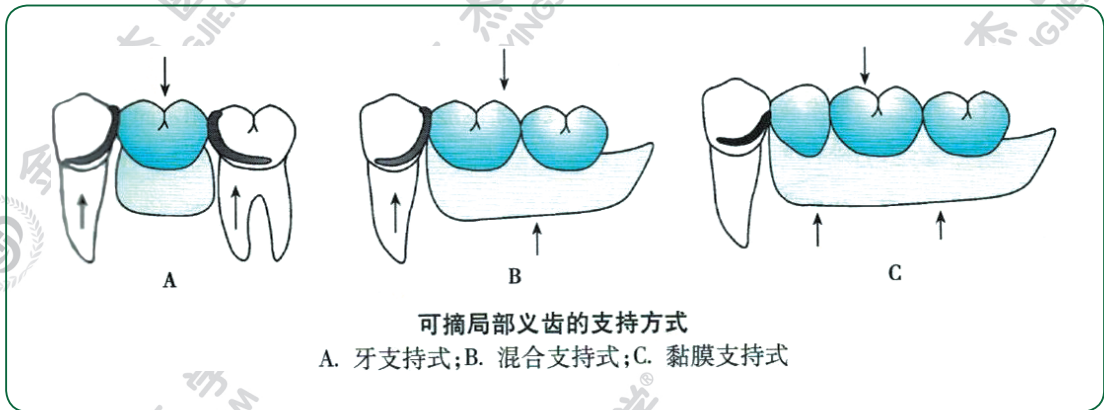


Z 成形术示意

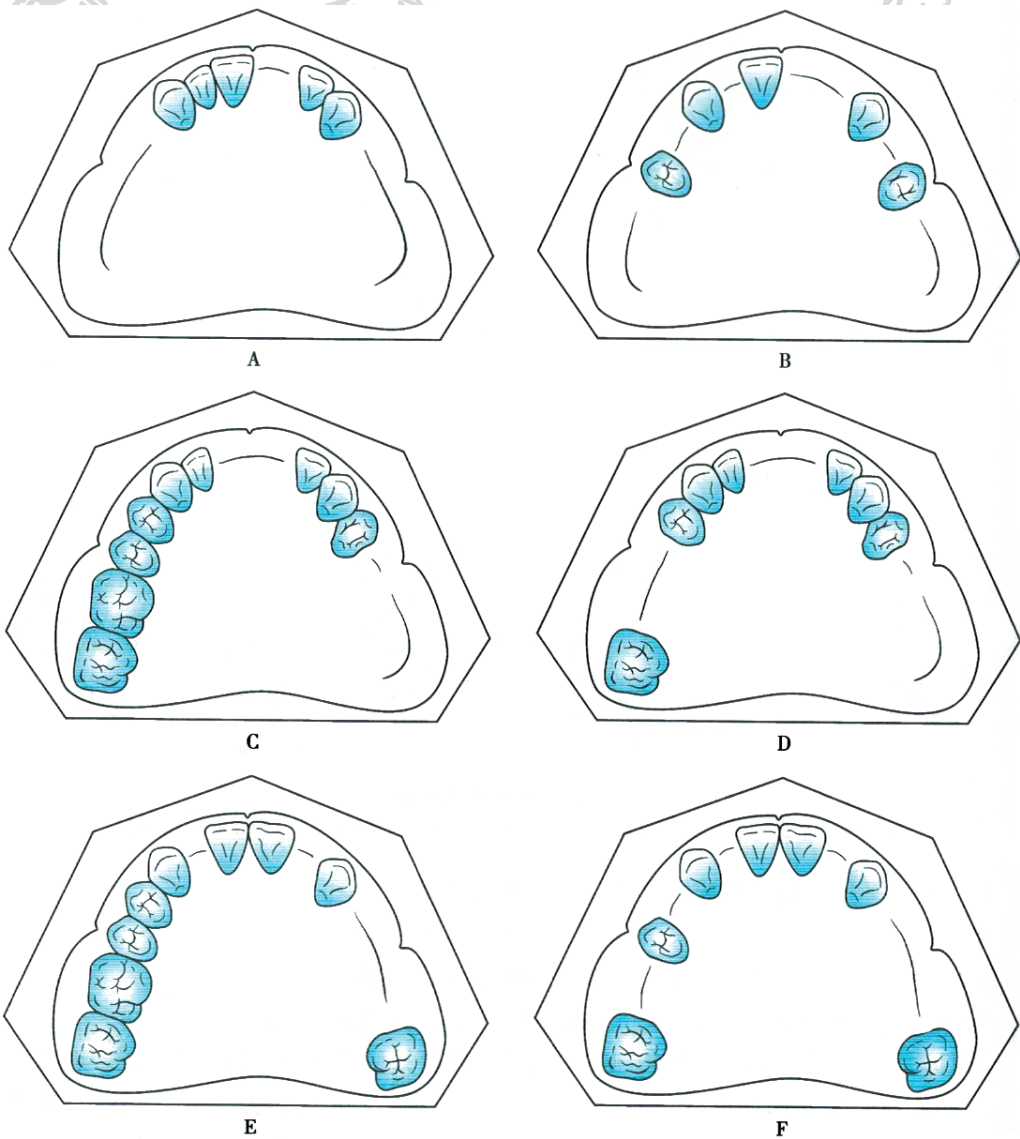


# 口腔修复学



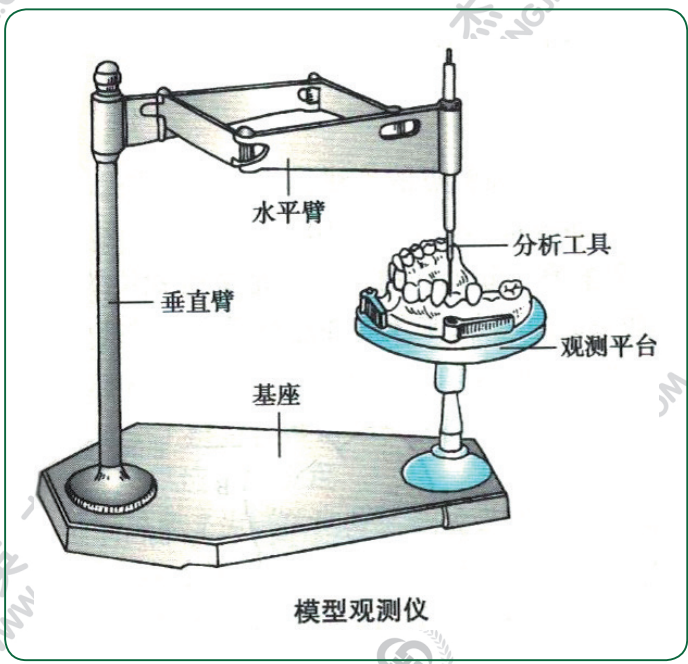
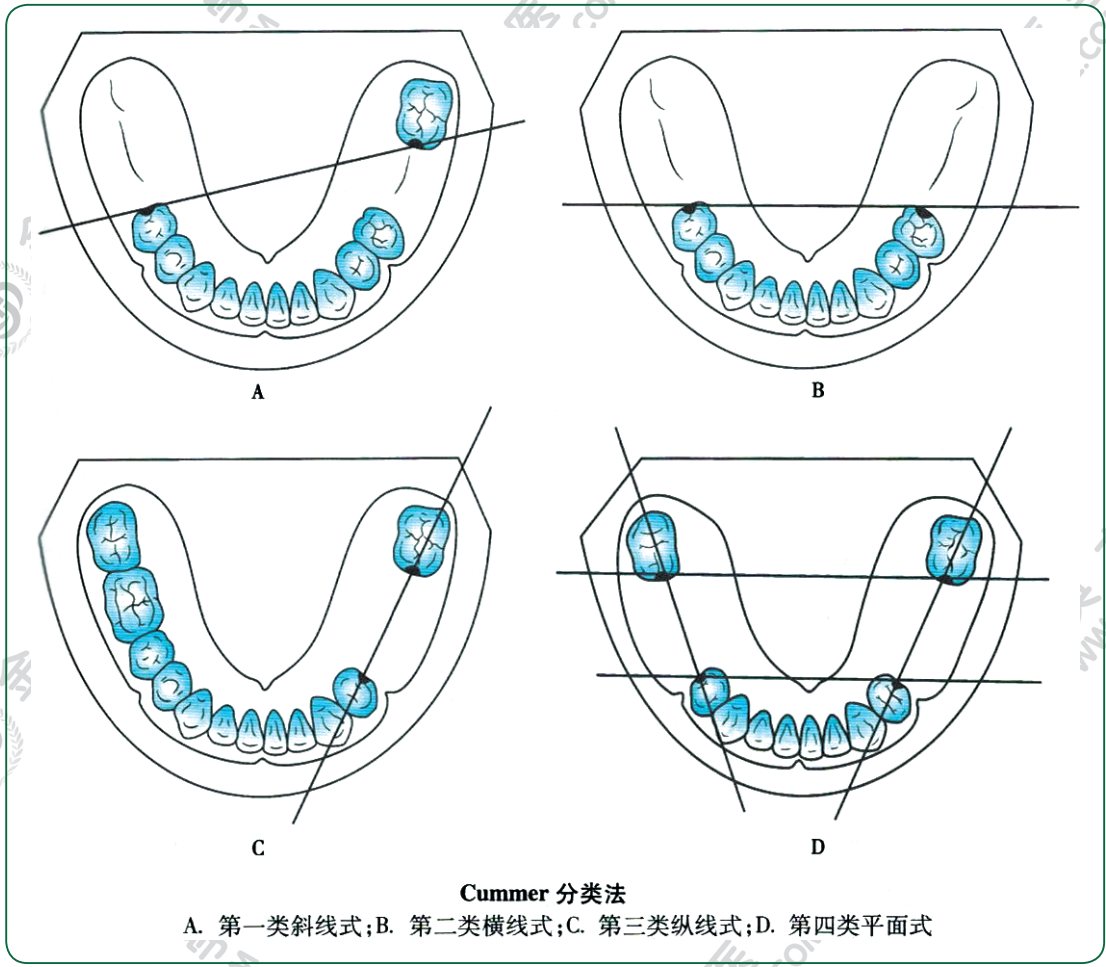


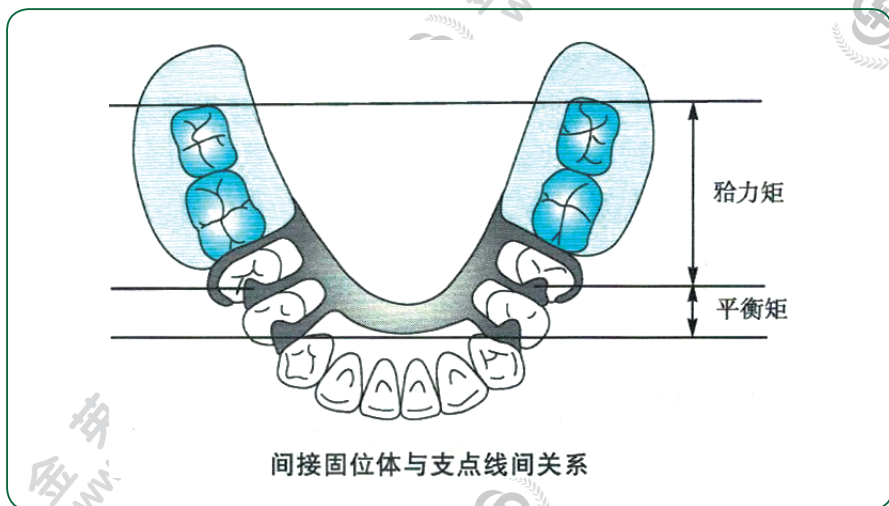
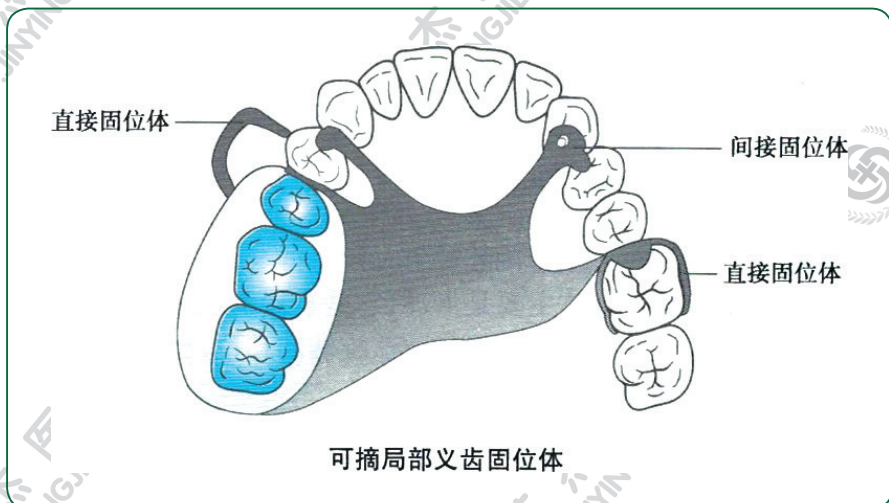
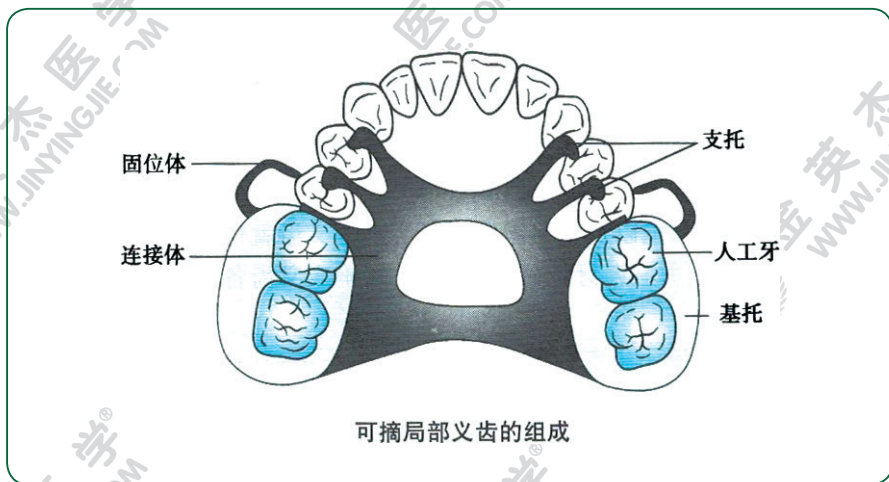


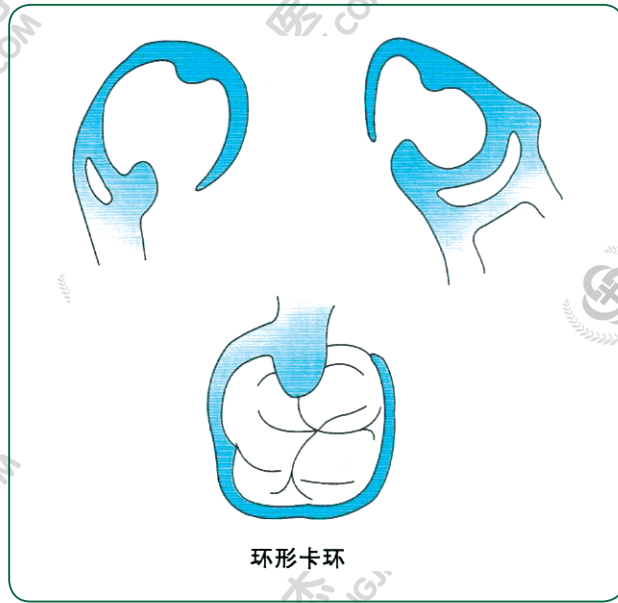


**Kennedy 分类的亚类**

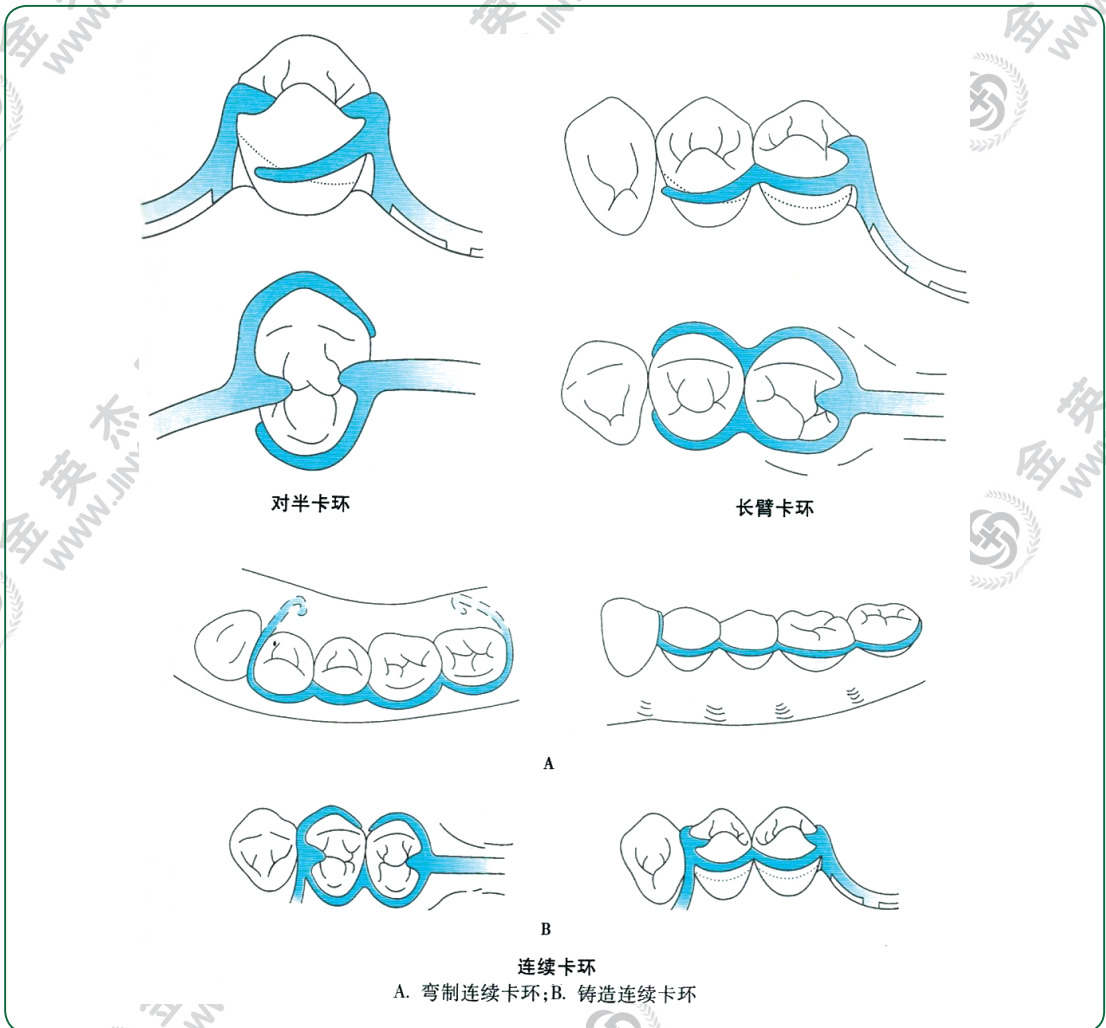
A. Kennedy 第一类第一亚类; B. Kennedy 第一类第四亚类; C. Kennedy 第二类第一亚类; D. Kennedy 第二类第二亚类; E. Kennedy 第三类第二亚类; F. Kennedy 第三类第四亚类







环形卡环



对半卡环

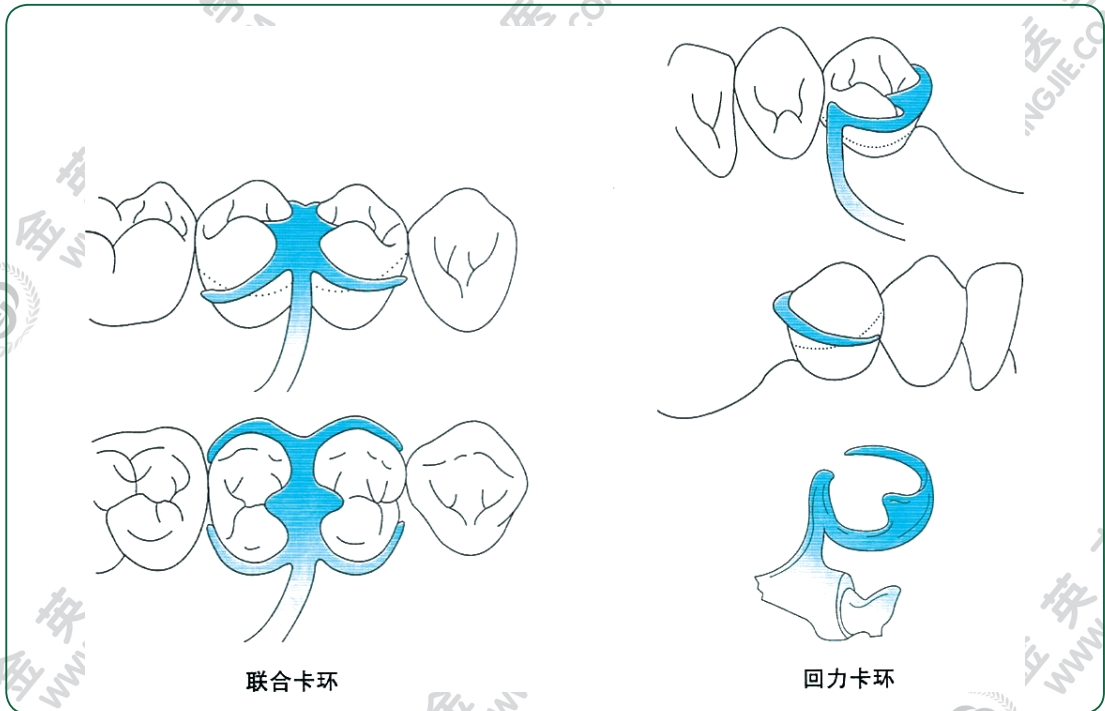
长臂卡环

A

B

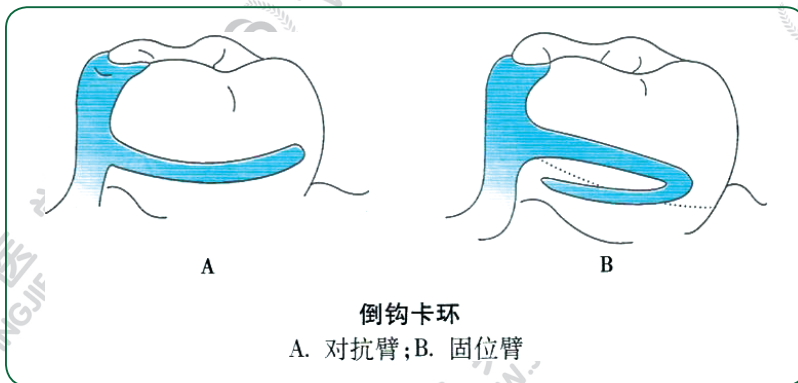
连续卡环

A. 弯制连续卡环; B. 铸造连续卡环



联合卡环

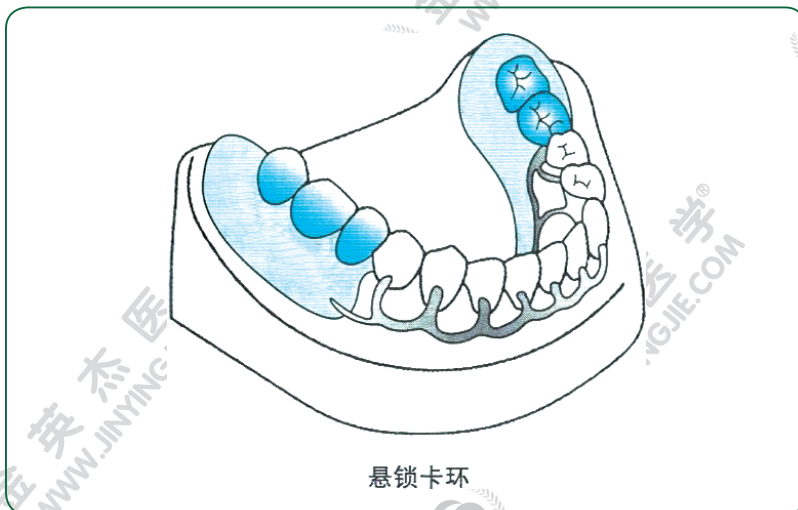
回力卡环



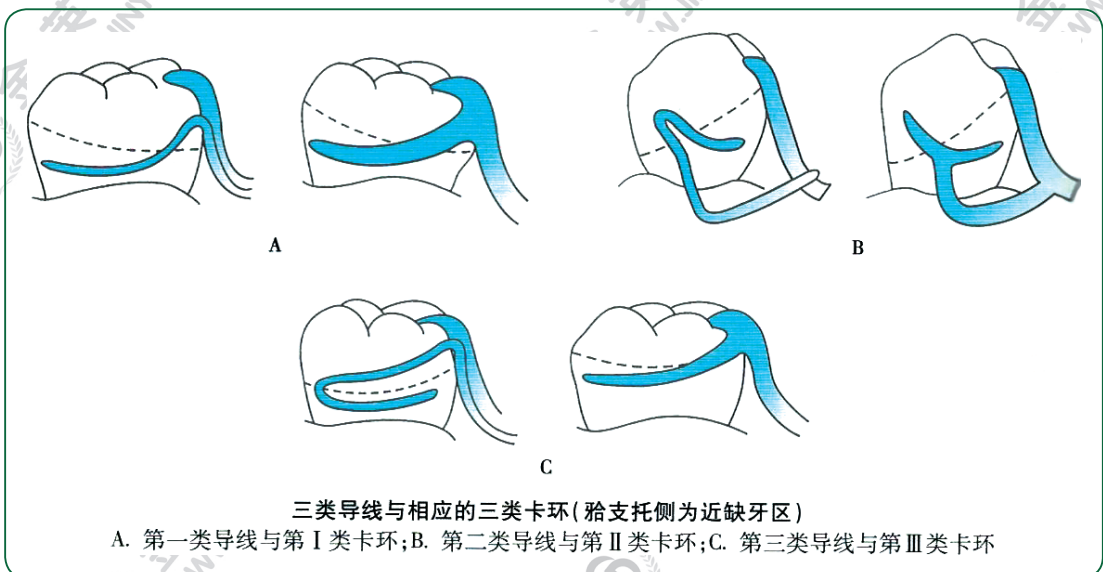
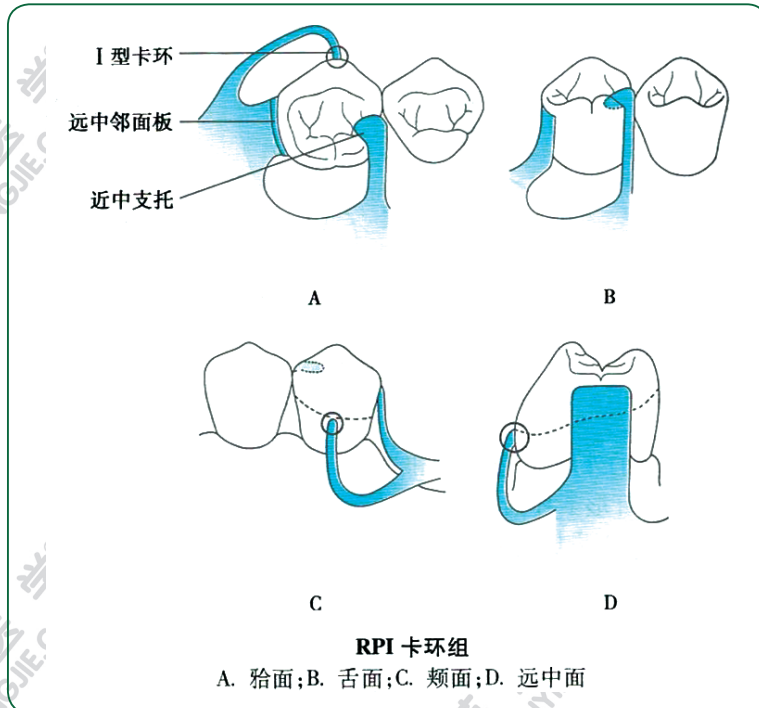
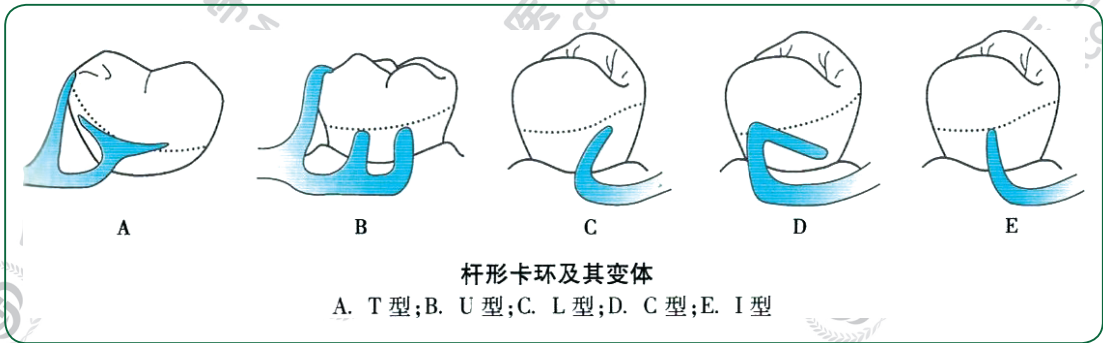
A

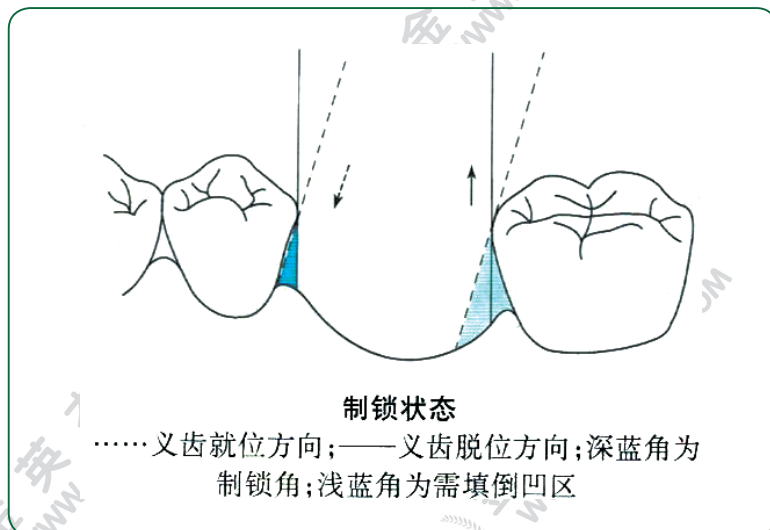
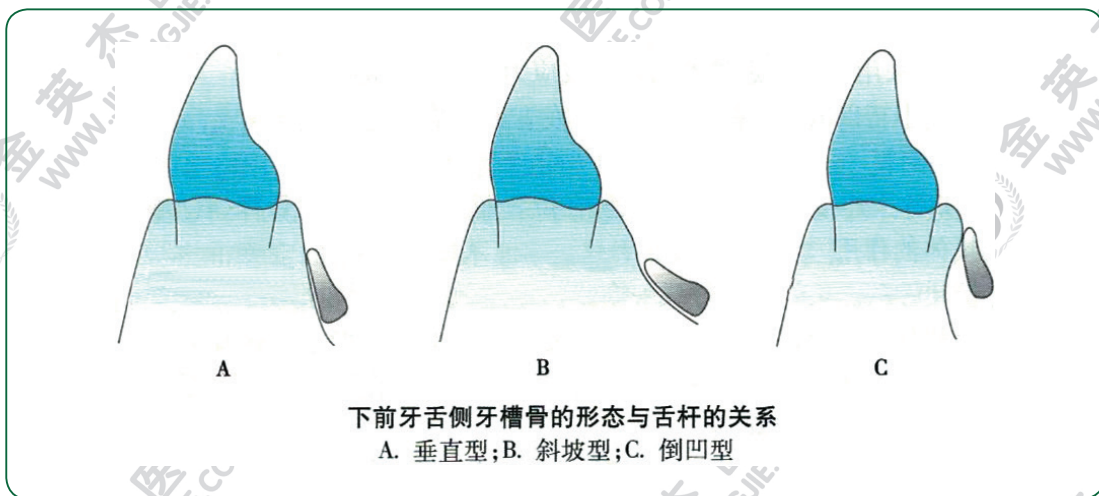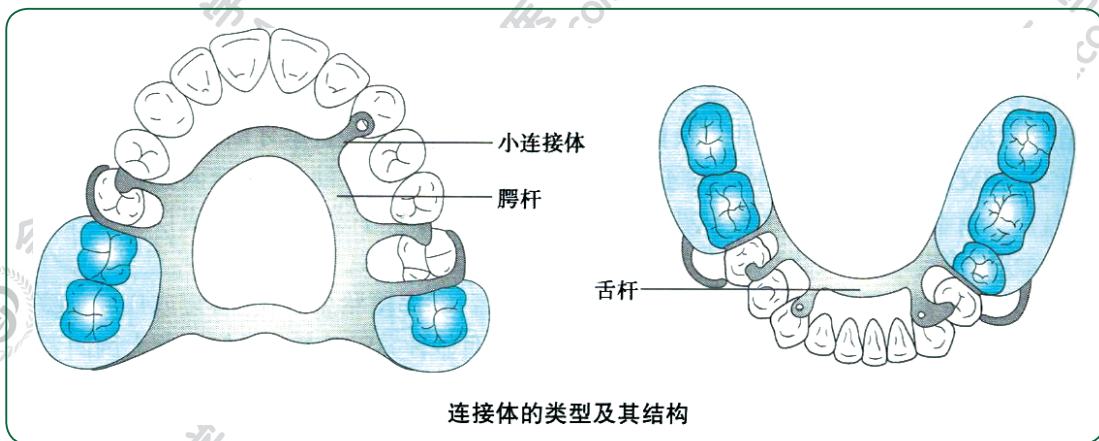
B

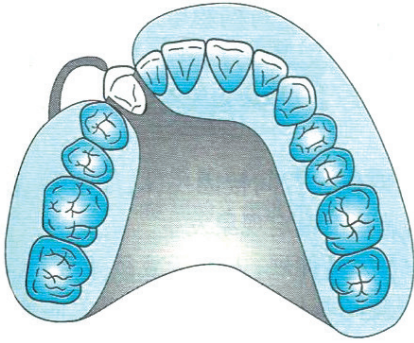
倒钩卡环  
A. 对抗臂; B. 固位臂



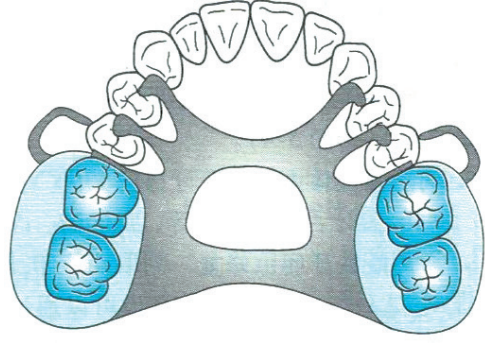
悬锁卡环



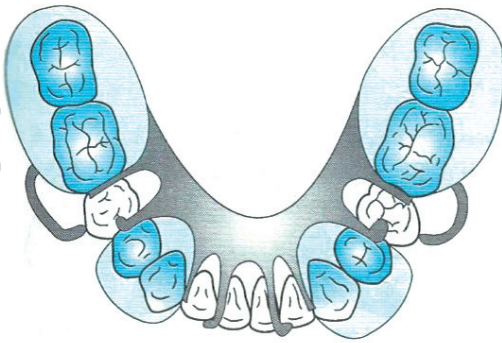




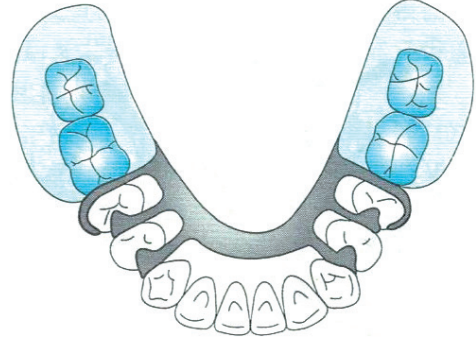
上颌 Kennedy 第一类牙列缺损的  
义齿设计



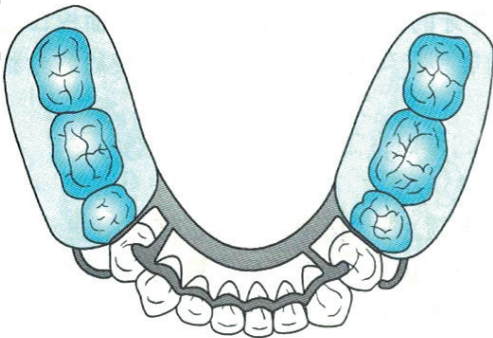
上颌 Kennedy 第一类牙列缺损的  
义齿设计



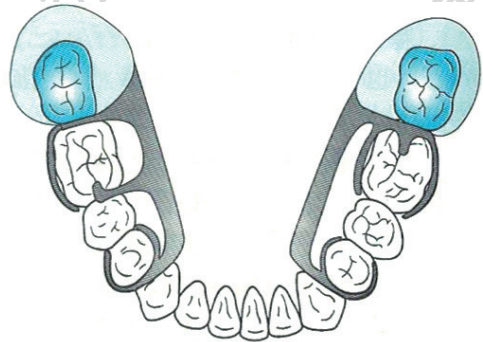
下颌 Kennedy 第一类牙列  
缺损的义齿设计



下颌 Kennedy 第一类牙列  
缺损的义齿设计

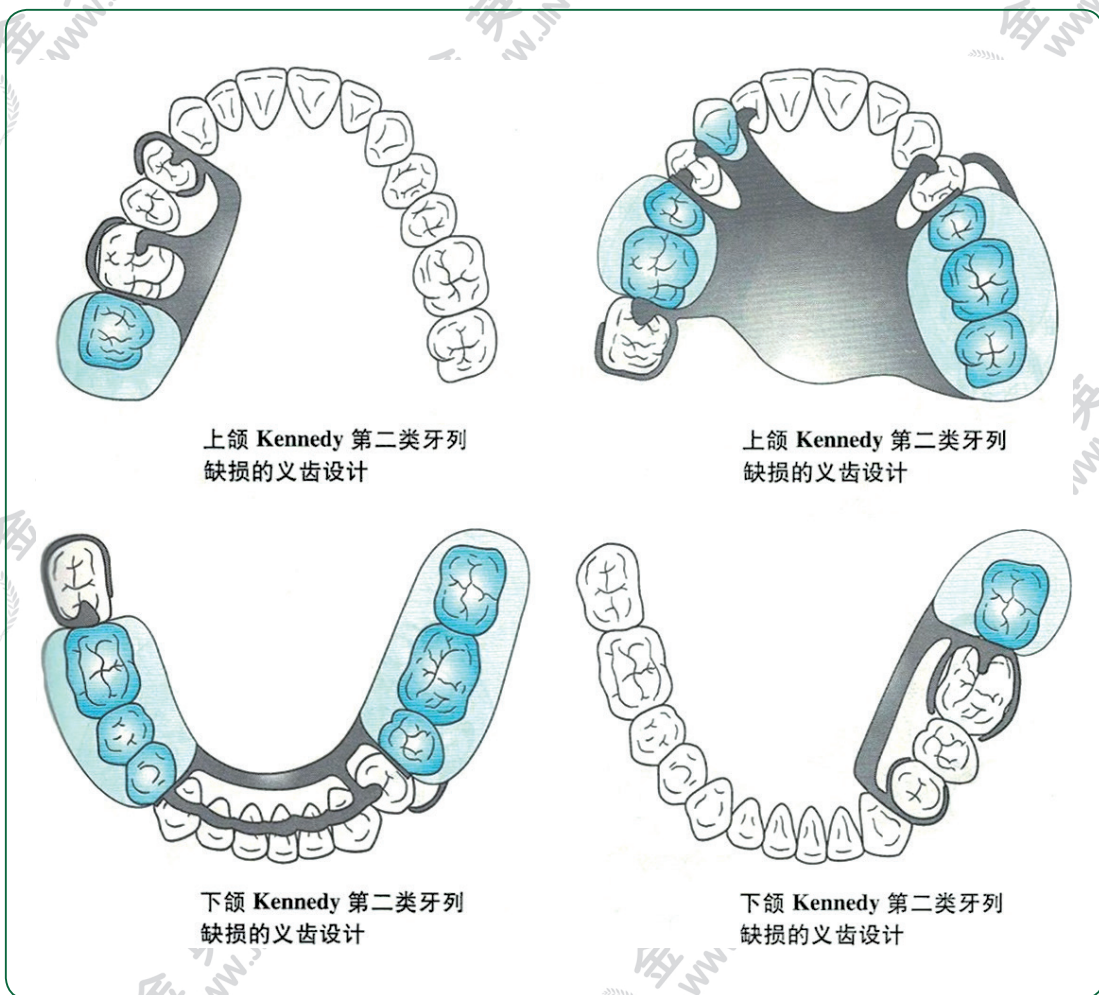
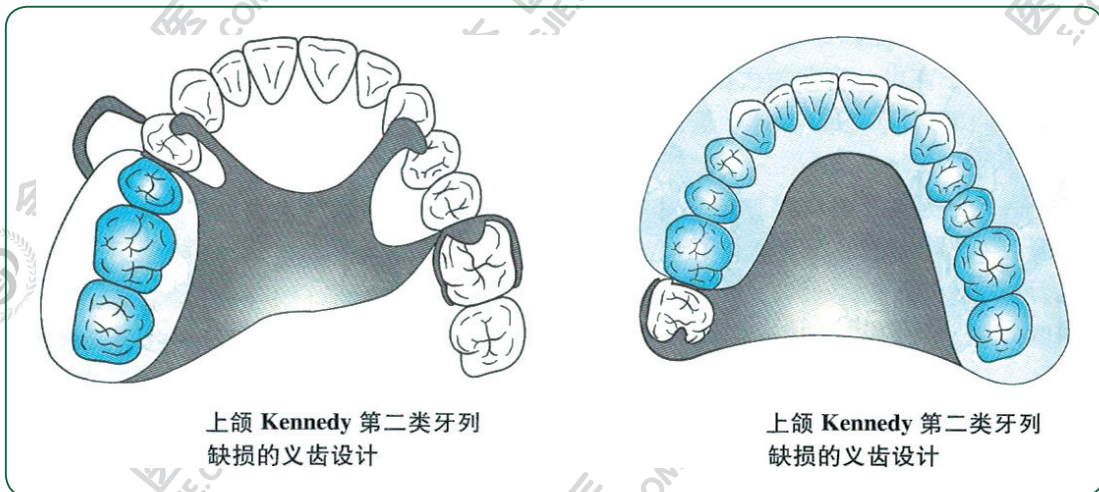


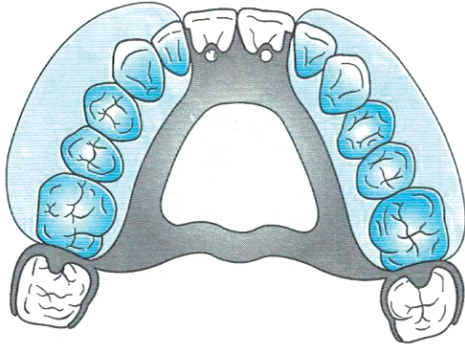
下颌 Kennedy 第一类牙列  
缺损的义齿设计



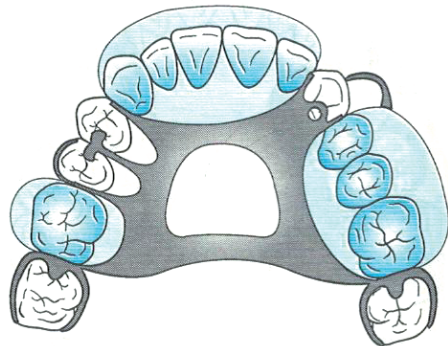
下颌 Kennedy 第一类牙列  
缺损的义齿设计



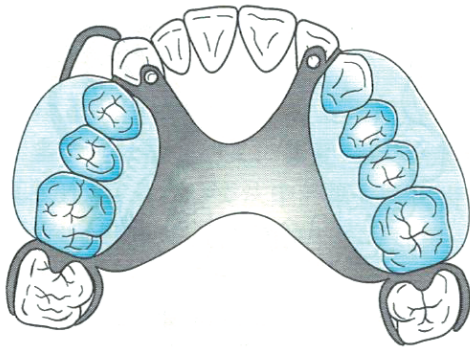




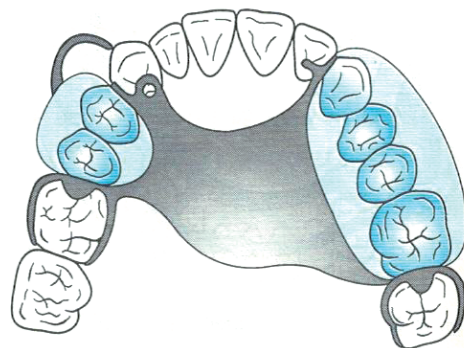
上颌 Kennedy 第三类牙列  
缺损的义齿设计



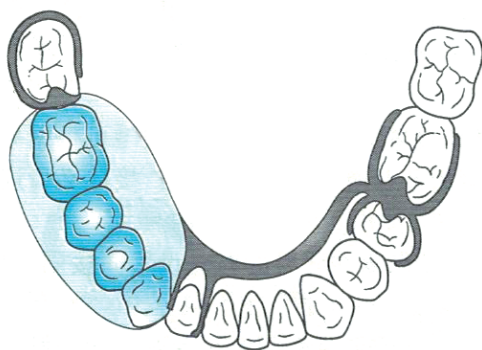
上颌 Kennedy 第三类牙列  
缺损的义齿设计



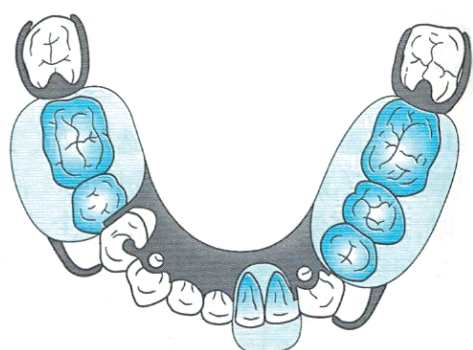
上颌 Kennedy 第三类牙列  
缺损的义齿设计



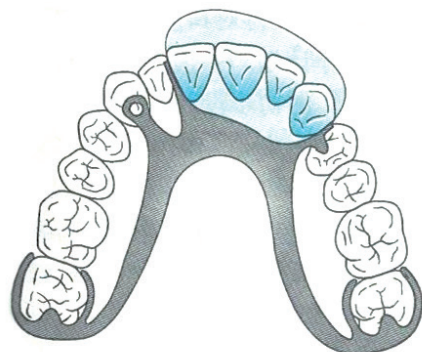
上颌 Kennedy 第三类牙列  
缺损的义齿设计



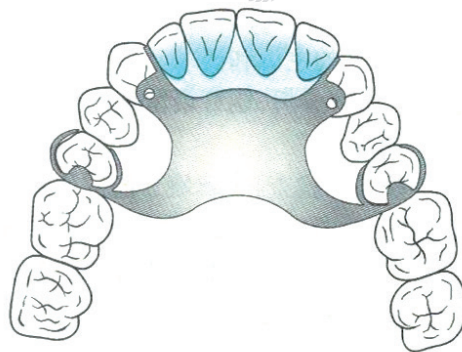
下颌 Kennedy 第三类牙列  
缺损的义齿设计



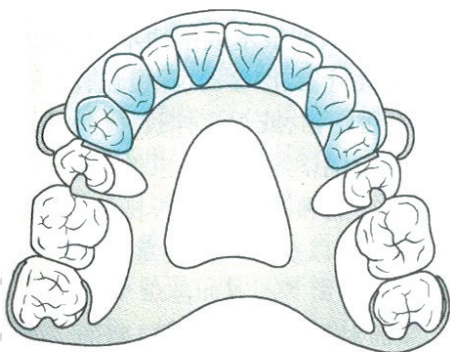
下颌 Kennedy 第三类牙列  
缺损的义齿设计



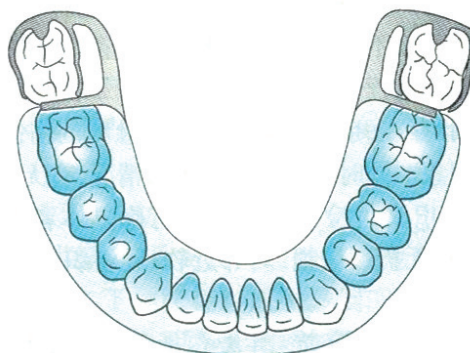
上颌 Kennedy 第四类牙列  
缺损的义齿设计



上颌 Kennedy 第四类牙列  
缺损的义齿设计

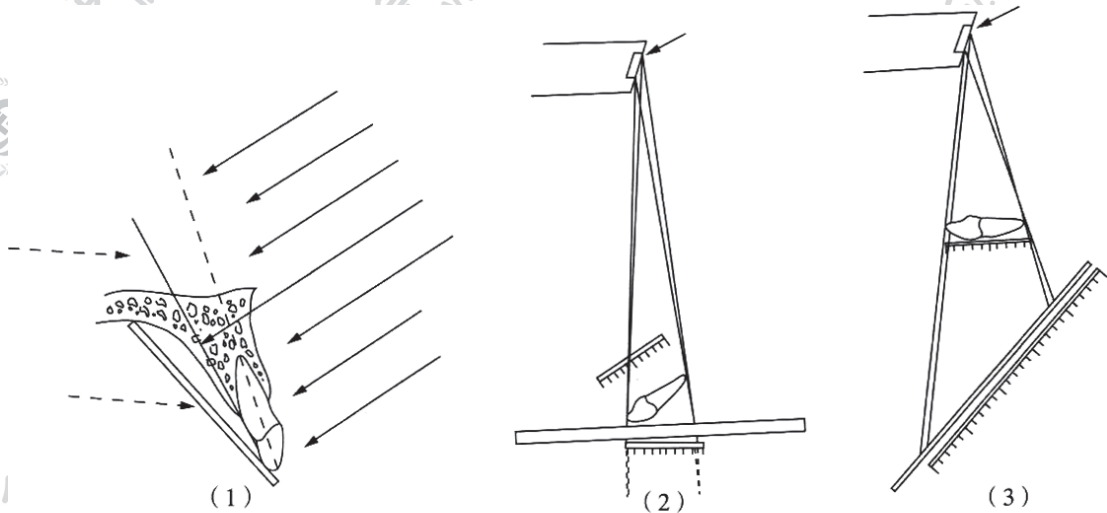


上颌 Kennedy 第四类牙列  
缺损的义齿设计



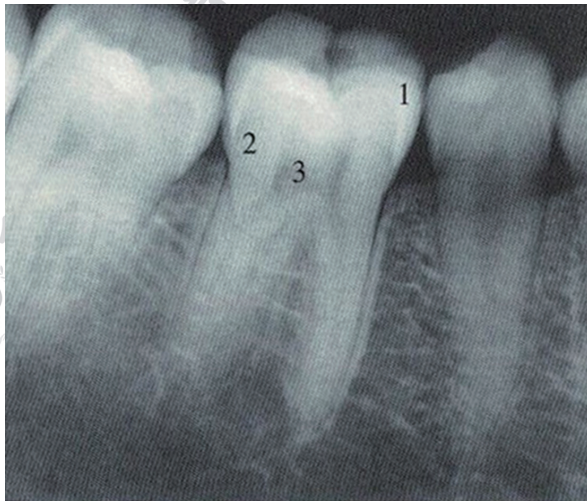
下颌 Kennedy 第四类牙列  
缺损的义齿设计

# 口腔颌面影像诊断学



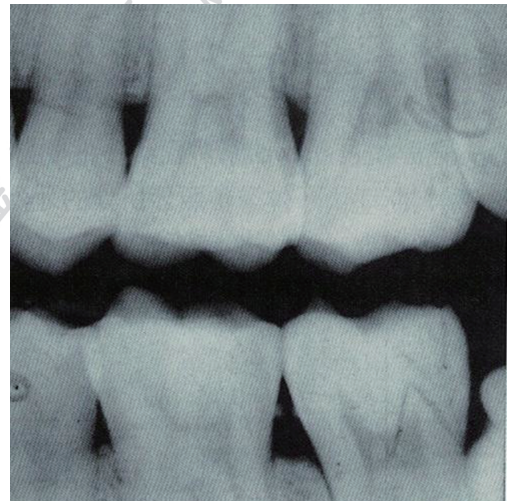
分角线投照技术原理示意图

- (1) X线中心线垂直于被照牙与胶片夹角的角平分线；(2) X线中心线垂直于胶片，牙体影像缩小；  
(3) X线中心线垂直于被照牙体，则牙体影像放大

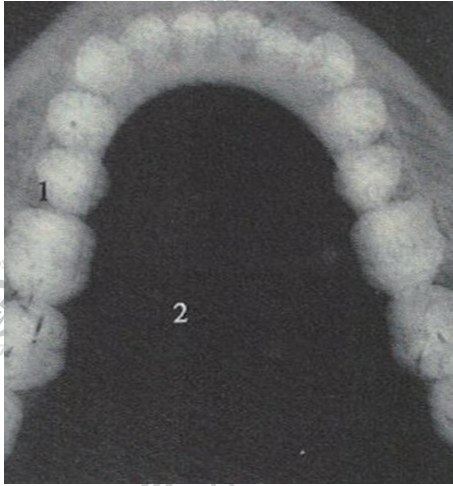


下颌后牙根尖片

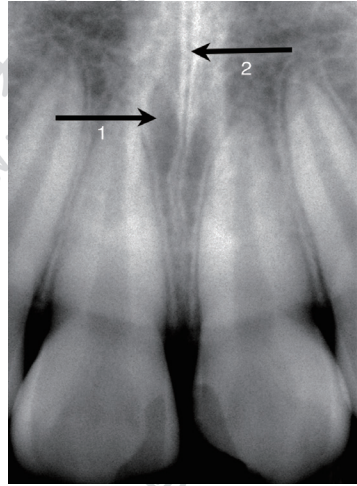
- (1) 牙釉质；(2) 牙本质；(3) 髓腔



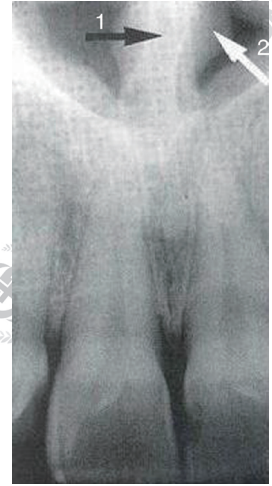牙合翼片



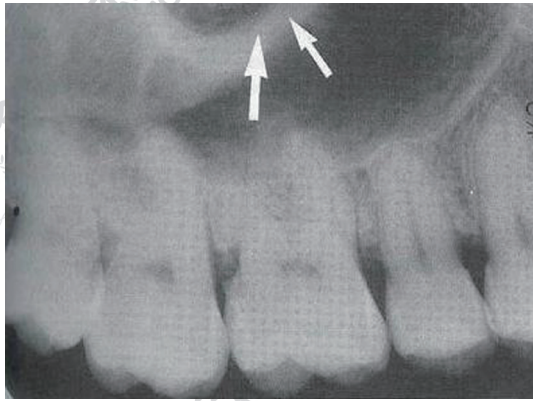
下颌横断牙合片



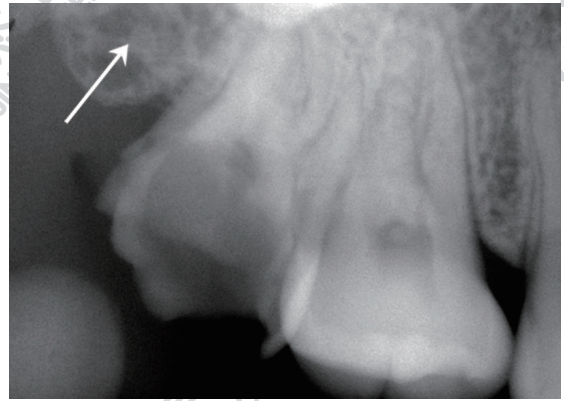
1. 切牙孔 2. 腭中缝



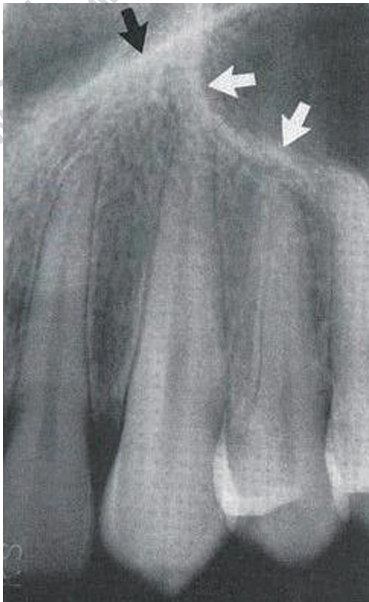1. 鼻中隔 2. 鼻腔



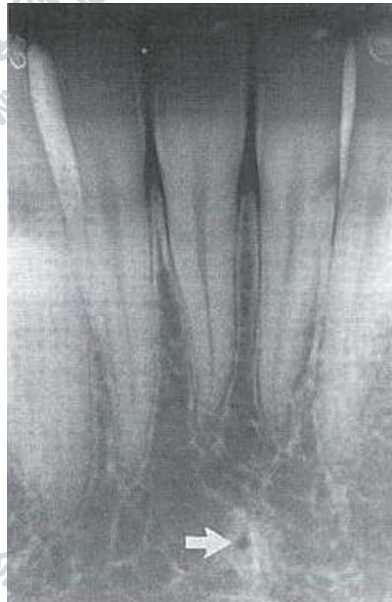颧骨



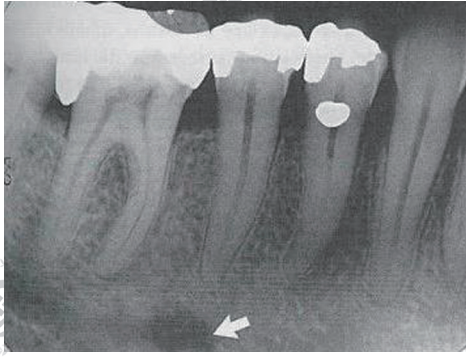
上颌结节



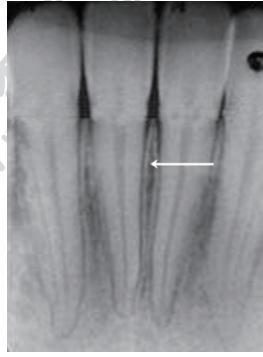
上颌窦



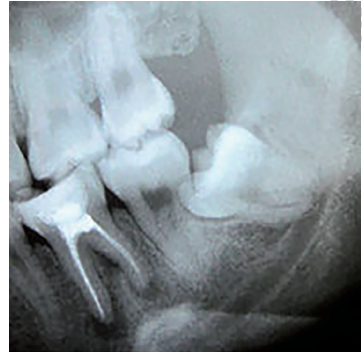颏棘



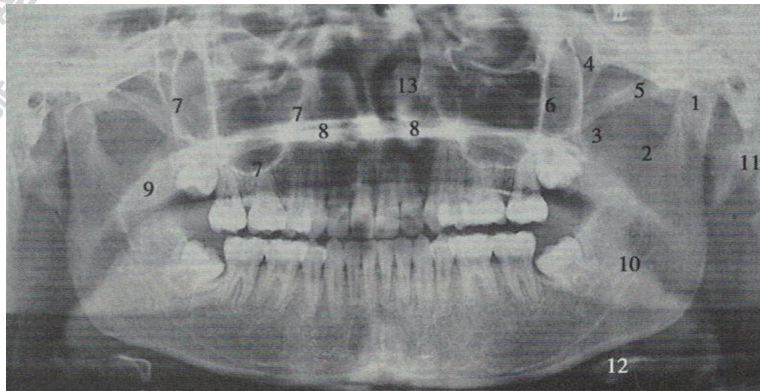
颞孔



营养管

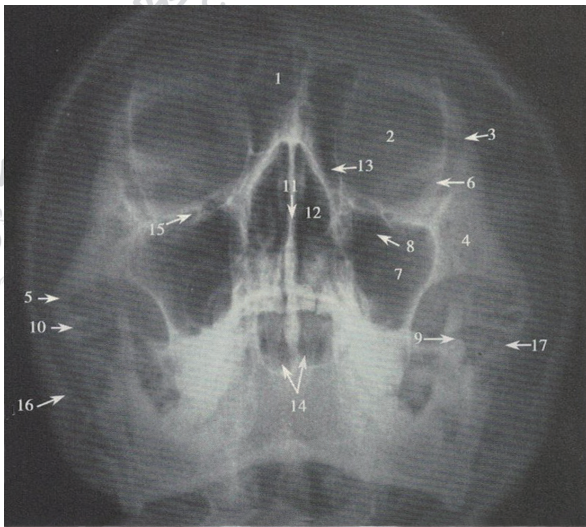


下颌管



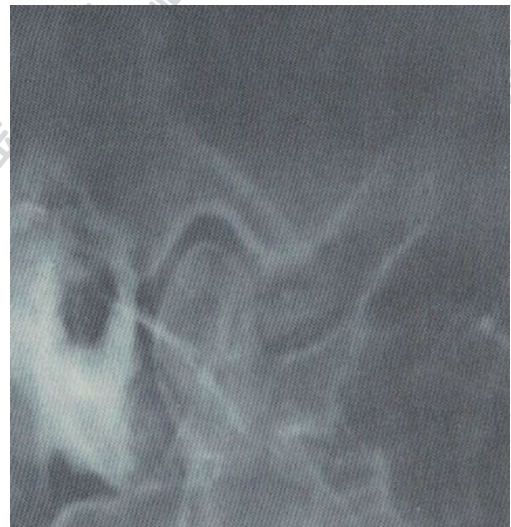
曲面体层片

1. 髁突; 2. 乙状切迹; 3. 喙突; 4. 翼腭窝; 5. 颧弓; 6. 颧骨; 7. 上颌窦; 8. 硬腭;  
9. 软腭; 10. 下颌管; 11. 茎突; 12. 舌骨; 13. 鼻腔

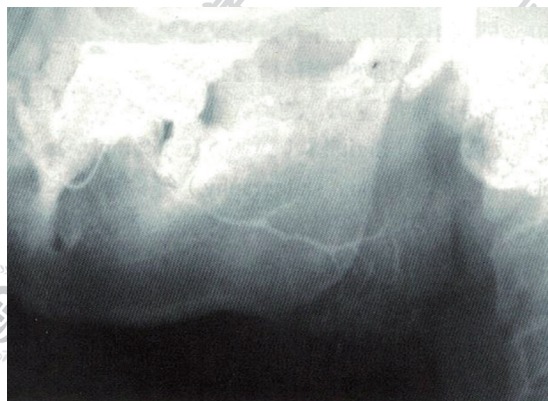

正常华特位图像

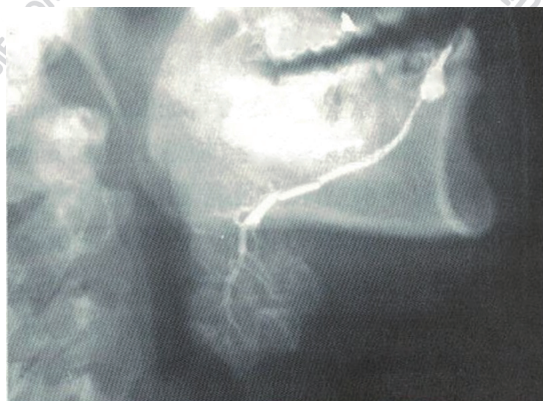1. 额窦; 2. 眼眶; 3. 颧额缝; 4. 颧骨; 5. 颧弓; 6. 无名线; 7. 上颌窦;  
8. 眶上裂; 9. 喙突; 10. 关节结节; 11. 鼻中隔; 12. 鼻腔; 13. 筛窦;  
14. 蝶窦; 15. 眶下孔; 16. 乳突蜂房; 17. 髁突;



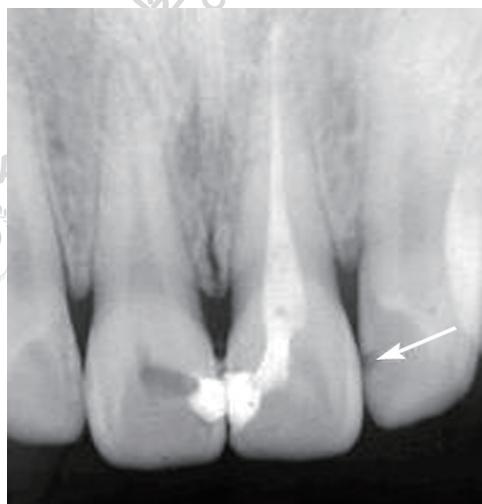许勒位



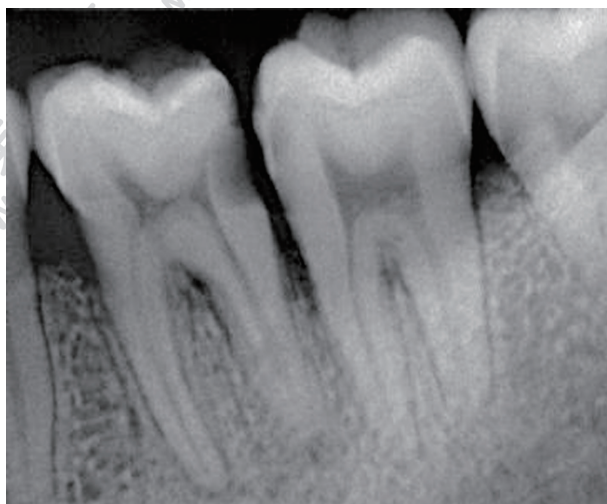
腮腺造影



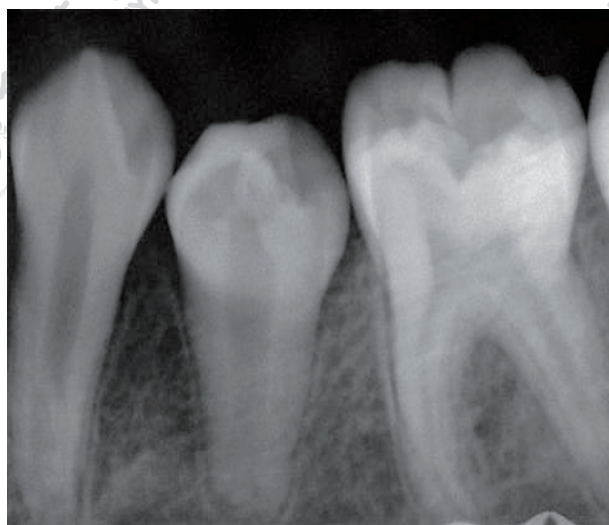下颌下腺造影



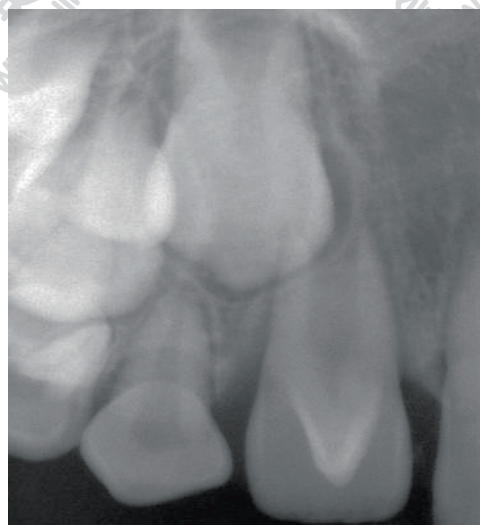浅龋



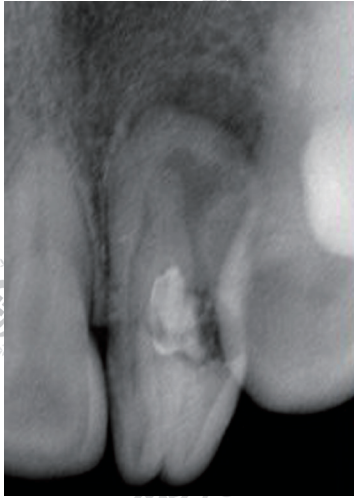深龋



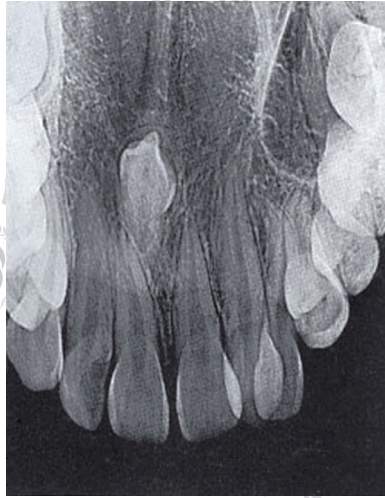
畸形舌侧尖



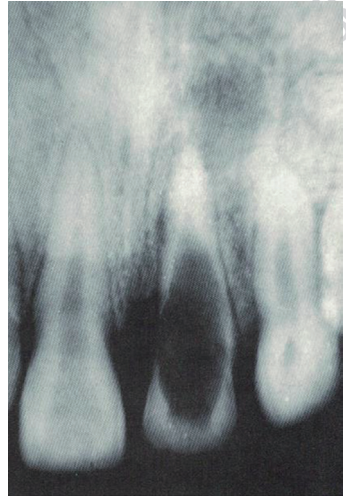
畸形舌侧尖



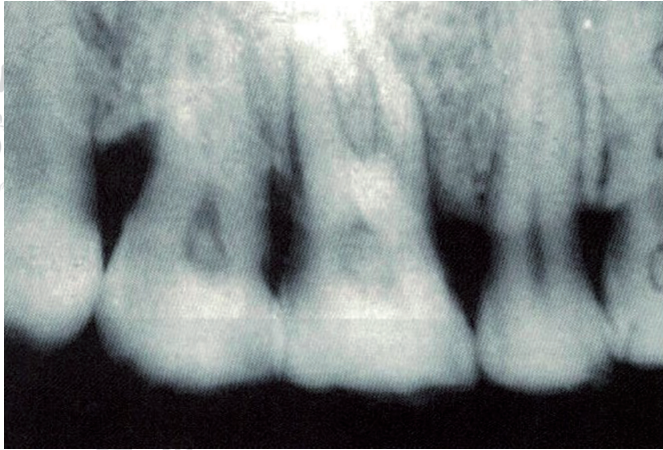牙中牙



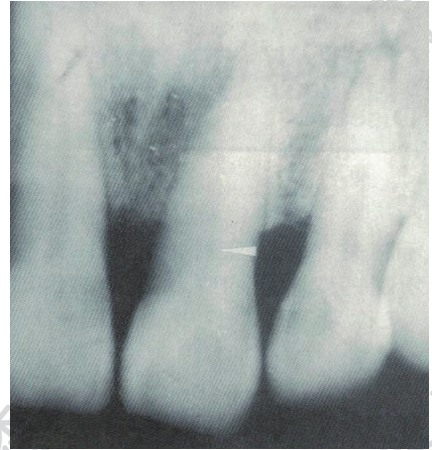额外牙



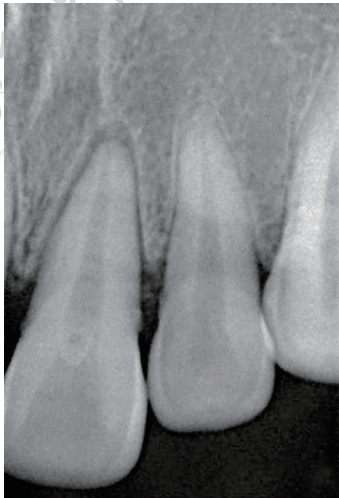
牙内吸收



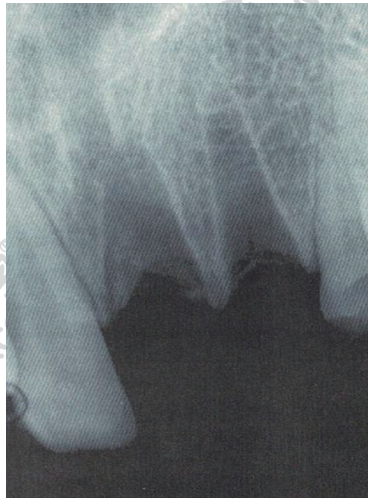
髓石



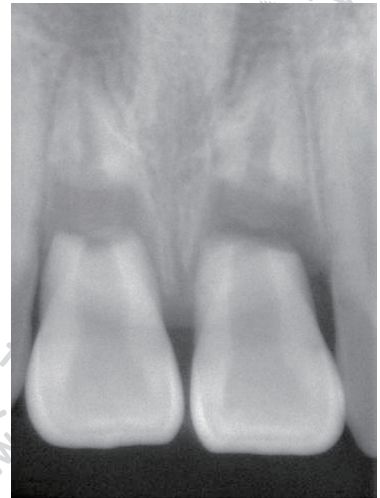牙髓钙化



牙脱位

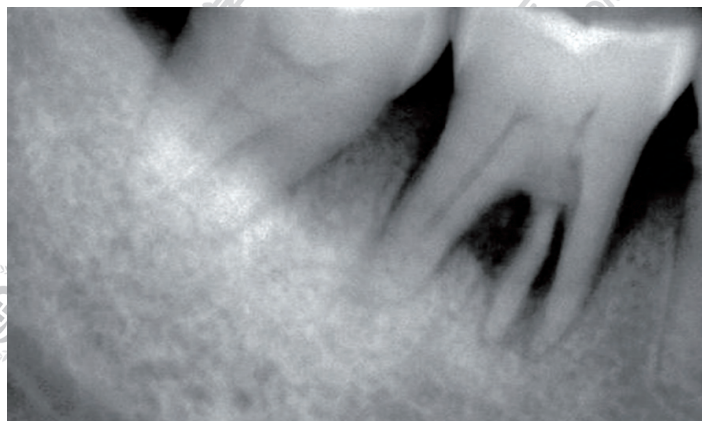


牙脱位

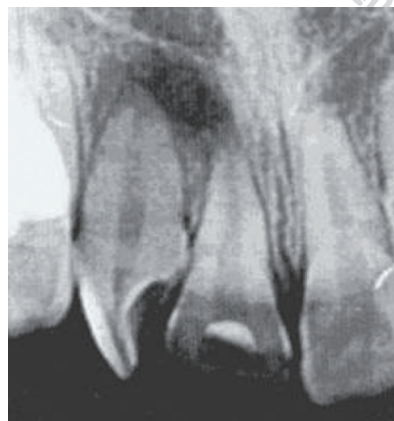

牙折

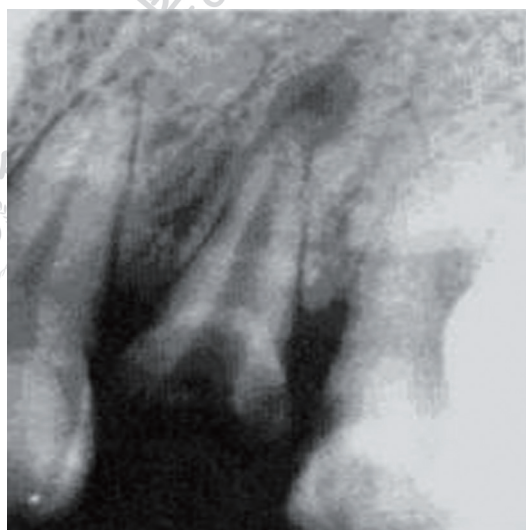




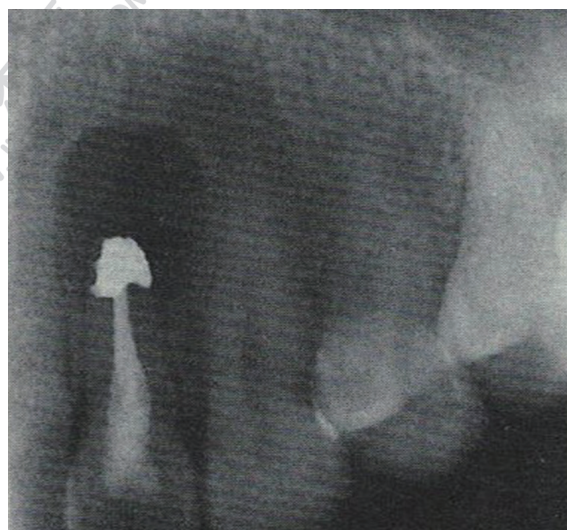
牙根折裂



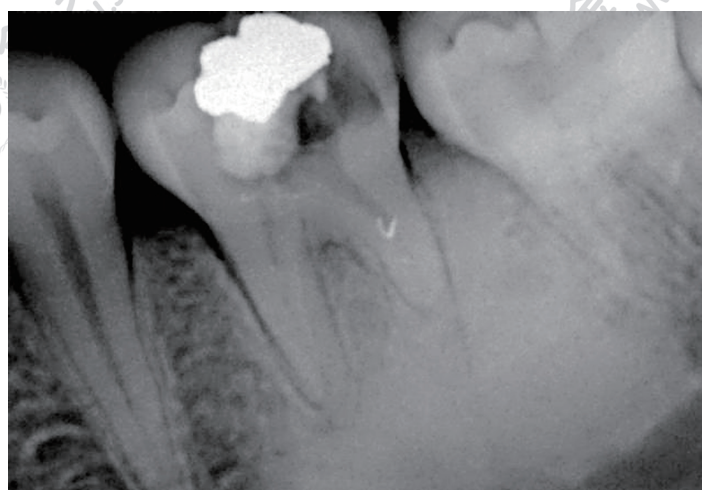根尖周脓肿



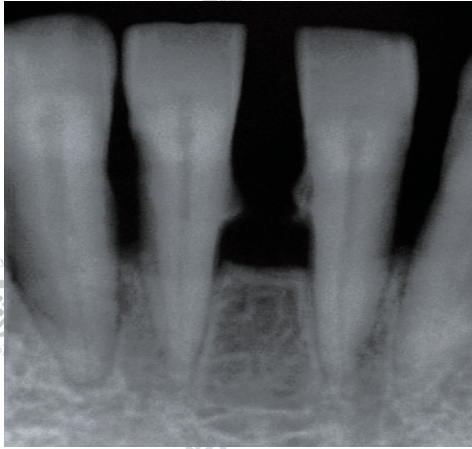
根尖周肉芽肿



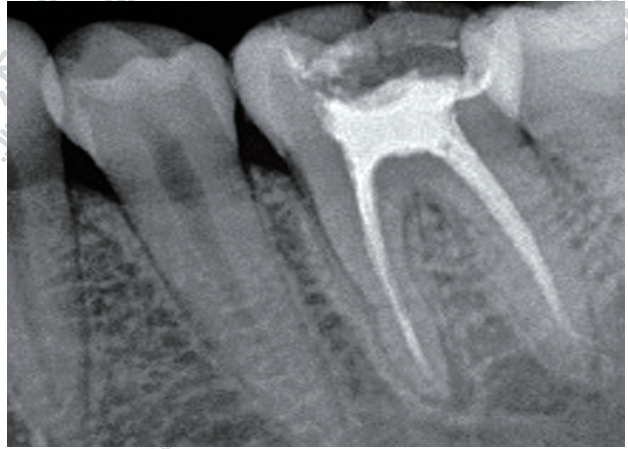根尖周囊肿



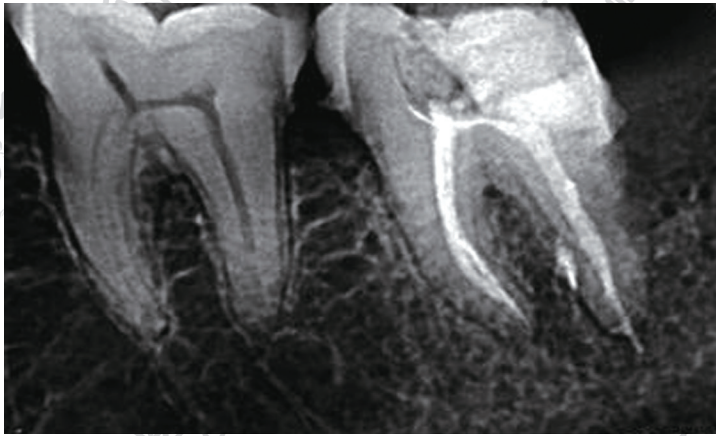
牙骨质增生



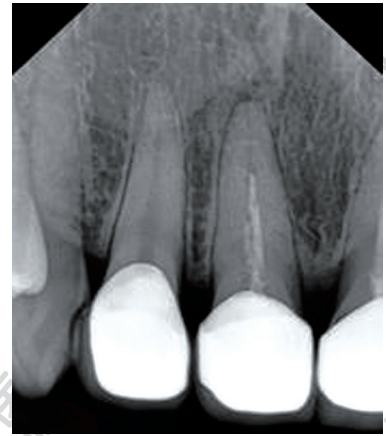牙周炎



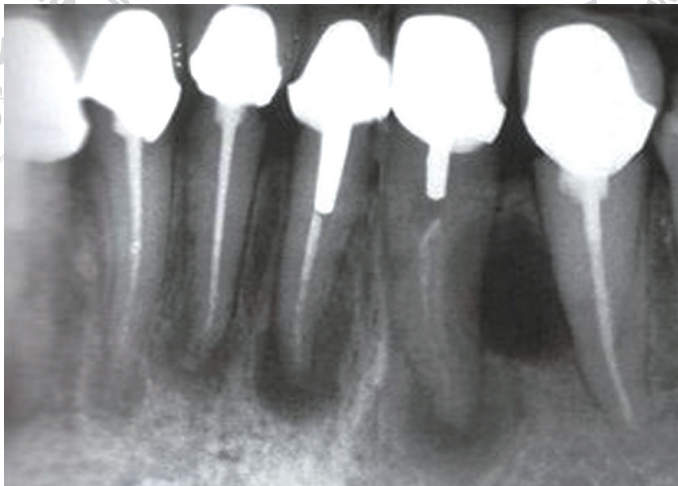
恰填



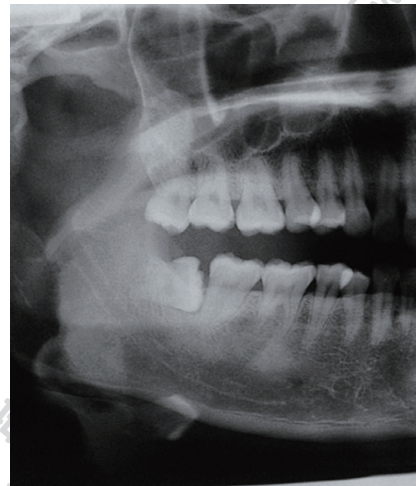超填



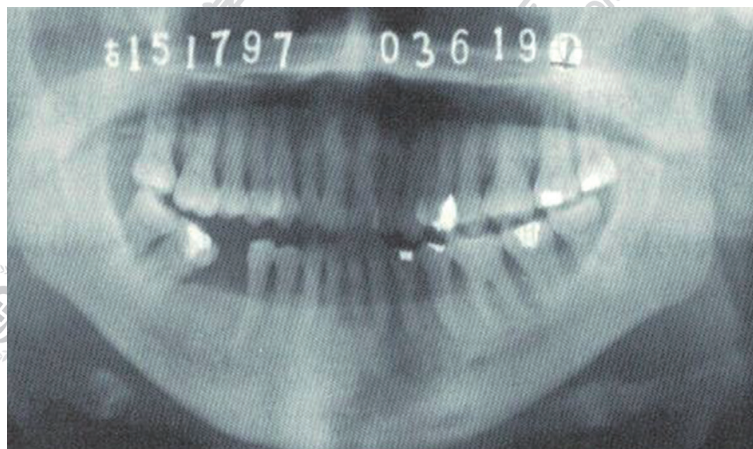欠填



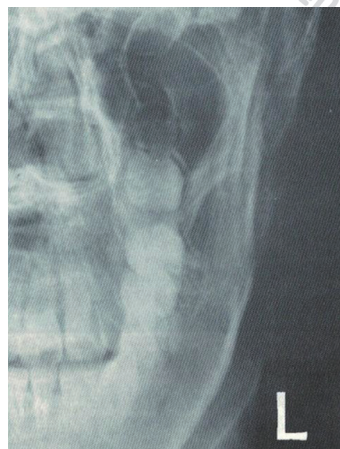充填不严密



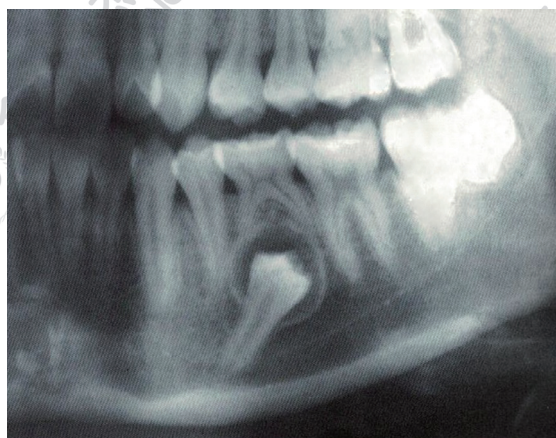第三磨牙阻生



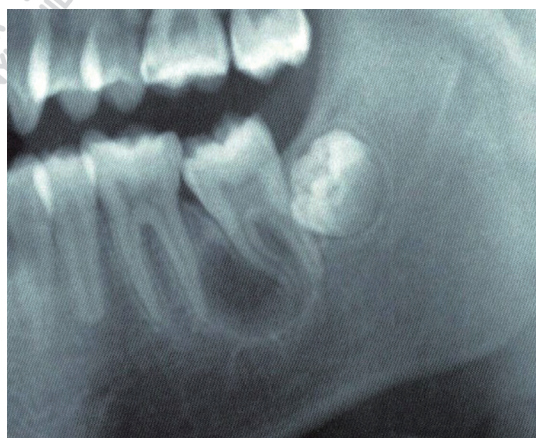
中央性颌骨骨髓炎



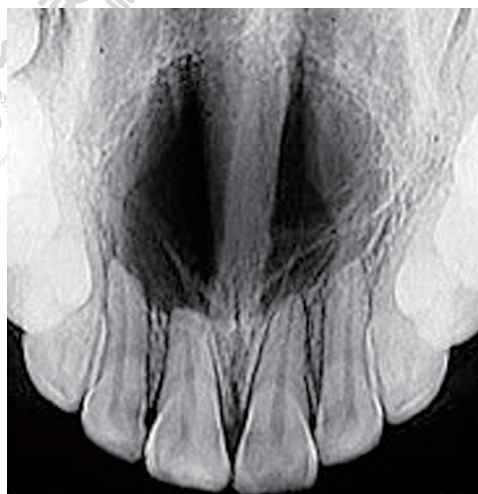边缘性颌骨骨髓炎



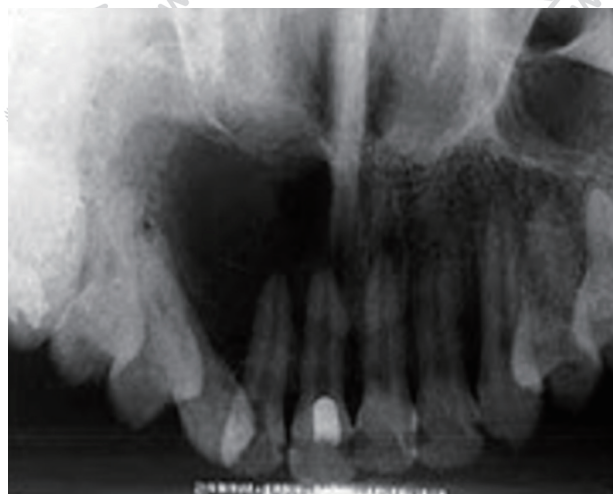
含牙囊肿



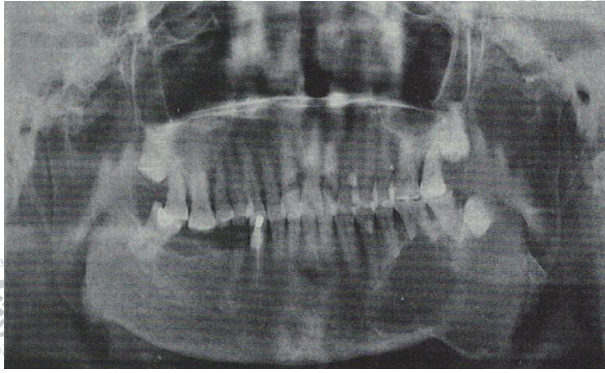
根侧囊肿



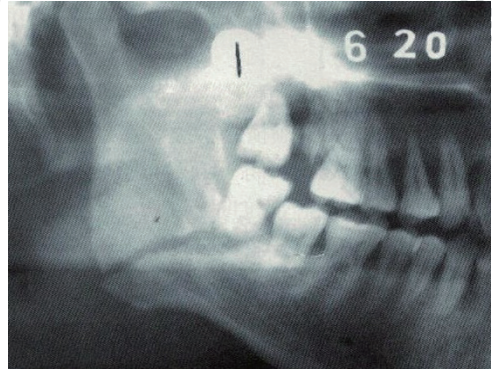
鼻腭囊肿



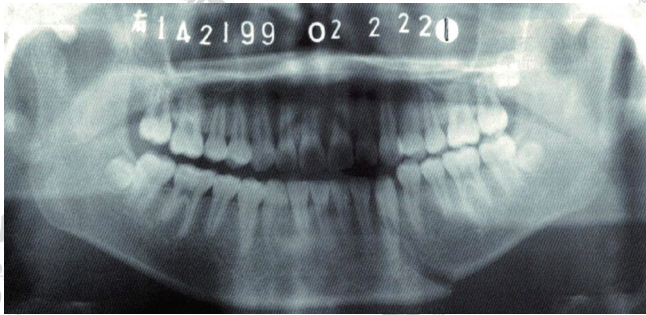
球上颌囊肿



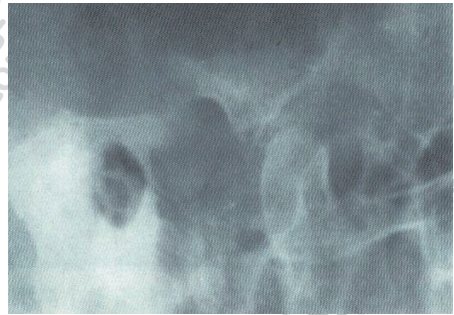成釉细胞瘤



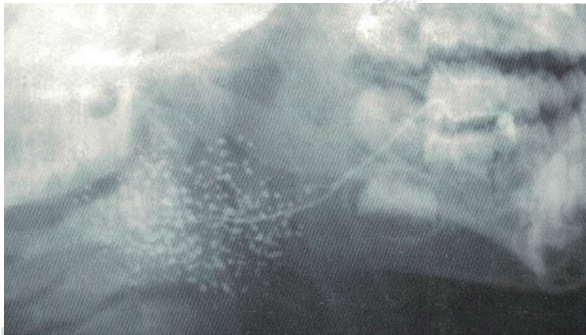下颌角骨折



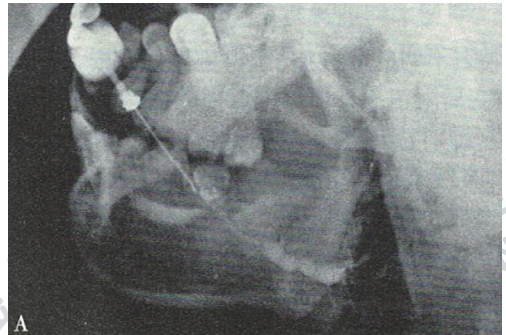
颧孔区骨折



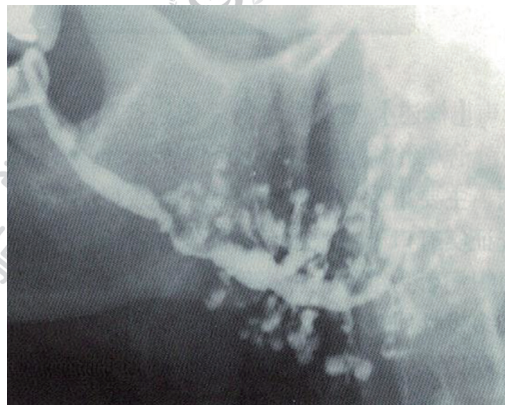
颞下颌关节脱位



慢性复发性腮腺炎



慢性阻塞性腮腺炎



舍格伦综合征